



## Original Article

## Computed Tomography Scan Images of Sphenoidal Sinus Septa and Their Relations to the Internal Carotid Artery

Zahid Sarfaraz Khan<sup>1</sup>, Sonia Umar Afridi<sup>1</sup>, Muhammad Ibrahim Afridi<sup>2</sup>, Fatima Daud<sup>3</sup>, Syed Abdul Basit<sup>4</sup>, Fatima Ali<sup>5</sup>, Muhammad Ateeq<sup>6</sup> and Irfan Ullah<sup>7\*</sup>

<sup>1</sup>Department of Anatomy, Khyber Girls Medical College, Khyber Pakhtoonkhwa, Pakistan

<sup>2</sup>Hayatabad Medical Complex, Khyber Pakhtoonkhwa, Pakistan

<sup>3</sup>Department of Anatomy, Pak International Medical College, Peshawar

<sup>4</sup>Department of Anatomy, Khyber Medical University, Peshawar, Pakistan

<sup>5</sup>Oral Maxillofacial Surgery Peshawar Dental College, Peshawar, Pakistan

<sup>6</sup>Institute of Biological Sciences, Sarhad University of Science & Information Technology, Peshawar, Pakistan

<sup>7</sup>Department of Life Sciences, School of Science, University of Management and Technology (UMT), Lahore, Pakistan

## ARTICLE INFO

**Key Words:**

Pain, Stress, University, Prevalence, Temporal

**How to Cite:**

Khan, Z. S. ., Afridi, S. U., Afridi, M. I., Daud, F. ., Abdul Basit, S. ., Ali, F. ., Ateeq, M. ., & Ullah, I. . (2022). Computed Tomography Scan Images of Sphenoidal Sinus Septa and Their Relations to the Internal Carotid Artery: CT Scan Images of Sphenoidal Sinus Septa. *Pakistan BioMedical Journal*, 5(4). <https://doi.org/10.54393/pbmj.v5i4.395>

**Corresponding Author:**

Irfan Ullah,  
 Department of Life Sciences, School of Science,  
 University of Management and Technology (UMT),  
 Lahore, Pakistan  
[irfan\\_btn@hotmail.com](mailto:irfan_btn@hotmail.com)

Received Date: 19<sup>th</sup> April, 2022

Acceptance Date: 25<sup>th</sup> April, 2022

Published Date: 30<sup>th</sup> April, 2022

## ABSTRACT

The trigeminal nerve and optic nerve, cavernous sinus optic chiasm, pituitary gland, and internal carotid artery are all encircled by the sphenoid sinus, which is located in the sphenoid. More than one asymmetrical vertical septa separate the sphenoidal sinus. Because of its position and linkages with important neurovascular and glandular systems, the sphenoid sinus poses a substantial diagnostic and therapeutic challenge. **Objective:** To look at the relationship between sphenoid sinus septation and the number and position of the internal carotid artery in people from Peshawar, Pakistan. **Methods:** The prospective study was conducted from November 2019 to April 2020 at the Radiology Department of a Khyber Teaching Hospital, Peshawar, the CT image was performed on 150 patients (100 males, 50 females) of the paranasal sinuses. From the originating axial slices, secondary coronal scans were obtained. Only individuals with no sphenoid sinus problems were included in the research to examine anatomical changes in the septation of the sphenoid sinus. **Results:** According to CT scans of the participants, 34% of males and 23% of females had more than one sphenoid septum, with 24 men accounting for 20.8 % and 16 female cases (16.8%) having the septum attached to the posterolateral wall of the sinus of the carotid canal. **Conclusions:** Prior to surgery, a CT scan of the paranasal sinuses is essential to rule out any potential complications caused by anatomical differences.

## INTRODUCTION

In the body of the sphenoid bone, the sphenoid sinus is located and is isolated from essential structures such as the optic nerve, optic chiasm, cavernous sinus, pituitary gland, and internal carotid artery by a thin plate of bone tissue [1]. The paranasal sinus (PNS) is responsible for lightening the skull, humidifying the inspired air, giving voice resonance, and acting as a buffer against face injuries. The sphenoid sinus (SS) is the most strategic of all the nasal sinuses, situated deep in the center of the skull. A

bony inter-sinus septum divides this asymmetrical paired and extremely variable sinus into right and left cavities [2]. For safe and high-quality functional endoscopic sinus surgery, appropriate diagnostics (primarily computed tomography and magnetic resonance imaging) are required before the procedure [3]. Computed tomography (CT) is frequently used by surgeons, particularly neurosurgeons to help them choose the best technique to avoid orbital or cerebral problems [4]. Besides minor

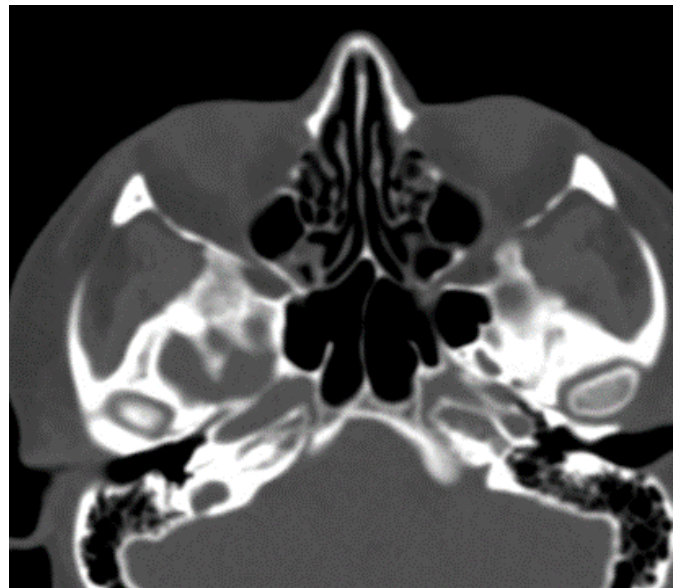anatomical variations are much more in the domain of anatomy and the appearance of variations that are easily recognized endoscopically (variations of the uncinate process, the presence of paradoxical curvature of the middle concha, concha bullosa, nasal septum deviation, etc.) it is extremely important, in the teamwork of anatomists, radiologists, and surgeons, to distinguish and define its most common or most dangerous major anatomical variations that can cause death [5]. In the preoperative examination of patients undergoing transsphenoidal surgery to remove pituitary tumors, CT is the gold standard. Currently, this method is used to eliminate approximately 95% of brain tumors. There is less surgical stress since the nasal cavity and sphenoid sinuses are used to approach and subsequently penetrate a broader pericellular area of the skull base. Transsphenoidal procedures may be used to remove tumors that have spread beyond the sella turcica and suprasellar region. Suprasellar, clivus, and cavernous sinus lesions may all be removed with this approach, which can also be used for resection of the clivus's lower boundary [6]. For endoscopic transsphenoidal approaches to the optic canal, the sphenoid septum, carotid artery, and skull base is critical [7]. The purpose of this study was to investigate the sphenoid sinuses' septation and the association between septa and the internal carotid artery's bony wall cover in adulthood.

## METHODS

The prospective study was conducted from November 2019 to April 2020 at the Radiology Department of a Khyber Teaching Hospital, Peshawar, the CT image was performed on 150 patients (100 males, 50 females) of the paranasal sinuses. Following informed consent, the participants were subjected to a CT scan of the PNS (General Electric [GE] Healthcare Computed Tomography Optima 660 system) as per departmental protocol, using a 3micrometres slice thickness and scan parameters of volts 120. Axial sections were obtained in a plane parallel to the hard palate from the upper dental arch to the roof of the frontal sinuses. The original axial slices were then used to develop secondary coronal scans which were developed with the help of Digital Imaging and Communications in Medicine (DICOM). A consultant radiologist with approximately 7 years of practical experience performed a detailed review of the scans. Any questions or misunderstandings were addressed through departmental consultation. Patients under the age of 16 years, those who already have sinus surgery, those who have had head and neck injuries, and those who have tumors or polyps in the nasal cavity or paranasal sinuses were all excluded from the study.

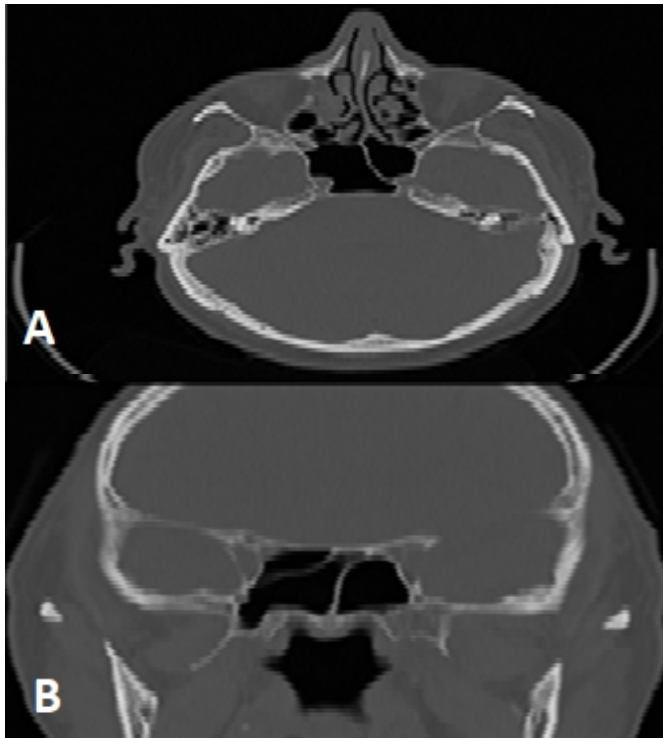
## RESULTS

The average mean age of patients was  $37.46 \pm 12.5$  years. Only four patients (4%) had no septum inside the sphenoid sinus, according to CT, 1 male and 3 females were included. The inter sphenoid septum was found in 96 percent of the applicants. In the intersphenoid, the main septum had 65 (66%) men. Eighty-five percent (82.8 percent) of axial male individuals (from 99 males with several septa) had the major septum located posteriorly rather than paramedially, on the left or right side, rather than being situated in the median line. Intersphenoid septum on the right had 58 (66.8%) of the 90 studied photos, whereas intersphenoid on the left had 32 (36.4 %). According to the 25 patients who reported having it, 22.7% of the 99 male patients with a validated intersphenoid septum had an additional auxiliary septum, resulting in two sphenoid sinuses. It was found in 14 instances to the right and 8 instances to the left of the so-called major septum. Three septa (one main and two accessory) were found in 9% of male patients. Six septa were found: one on each side of the major intersphenoid septum, three on each side of the main septum, and one on either side of the main septum itself. Sphenoid sinuses with quadruple septa (one main and three auxiliary) were found in four men (4.5 percent). "The schedule was as follows: in 3 cases - 2 right, 1 left from the main septum, in 1 case-2 left, 1 right of the main septum (Figure 1), and in 1 case all 3 accessory septa were located to the right of the main septum" The CT scans study of the patients, we have revealed that in 35 cases, there is more than one sphenoid septum in the sinus (34 percent). Because the occurrence of a septum had not been registered in one case, all of the following statistics refer to a sample of 99 male individuals.



**Figure 1:** Axial CT scan of a male patient's head. The sphenoid sinus has several septa

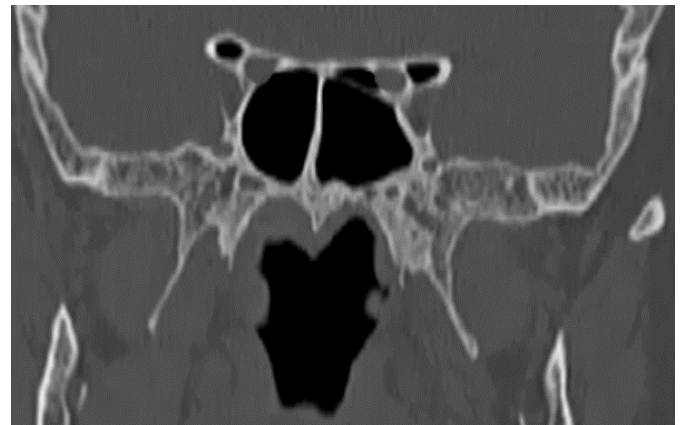In addition to determining the number of septa, especially those associated to the carotid canal on the sphenoid sinus's posterolateral wall. It is established that in men with one septum, one on the right and two on the left, it is inserted in the projection of the carotid canal. The insertion of accessory septa in the carotid canal was seen in 15 of the 25 men with accessory septa, six on the left and four on the right (Figures 2A,B). When expanding the carotid canal, four right and three left cases, totaling ten men and six women, each had two accessory septa as their starting point. Individuals with three accessory septa have an increased risk of developing carotid stenosis, which is a narrowing of the arteries that supply the brain and heart. The septum was found to be related to the carotid canal in 20.8 percent of the males examined, according to this study.



**Figures 2A,B:** Axial and coronal CT head scan of a male patient. Two septa at coronal scan, one inserts at the carotid canal that are also visualized at axial scan as well

The absence of a septum was discovered in three of the women's CT pictures. The major septum has 35 intersphenoid inter (70.8 %). The septum was located paramedially in 37 (79.2%) of the 47 females with intersphenoid septums, with 28 (59.8%) instances on the right and 16 (19.7%) cases on the left of the middle line. Twelve women (12.2 percent) had an accessory septum, with eight instances on the right and four on the left of the main septum, respectively. Using a subset of the data, three septa (two accessory and one major) were found in four instances. Aside from the primary septum, there were

accessory septa on the right and left in three cases, and an accessory septum on the right in one. As soon as three accessory septa were found, two of them were on the right and one of them was in a different place. Based on the analysis of CT images we conclude about existing more than one septum in the sphenoid sinus in 25 patients or 23%. In cases of existing three accessory septa in males and females, sphenoid sinuses were hiperpneumatized towards greater wings and pterygoid process. We also observed a transversal septum in the projection of the optic canal with the consecutive formation of the Onodi cell, which will be the subject of future studies(Figure 3).



**Figure 3:** Coronal CT head scan of a male patient. Transversal septum in the projection of left optic canal as well as pneumatization of anterior clinoid processes

Insertion of the septum to the posterolateral wall of sphenoid sinus in the projection of the carotid canal was registered in 16 female patients(16.8%) as shown in Table 2.

Number of Septa (Accessory and Main)	Carotid Canal	
	Left	Right
1	2	1
2	4	6
3	1	2
4	2	2
Total	9	11

**Table 1:** In male patients, the location of the primary and auxiliary septa toward the carotid artery is shown

Number of Septa (Main and Accessory)	Carotid Canal	
	Left	Right
1	1	1
2	4	5
3		4
4	1	1
Total	6	12

**Table 2:** In female patients, the location of the primary and auxiliary septa toward the carotid artery is shown

## DISCUSSION

The research is the first to reveal a link between sphenoid artery variance and internal carotid artery in the Pakistani population. The use of CT to determine the morphological changes of the sphenoid sinus and its correlation to surrounding structures such as the optic nerve, internal carotid artery, cavernous sinus, and pituitary glands, as well as his relationship to nearby structures such as the optic nerve, internal carotid artery, cavernous sinus, and pituitary glands, is crucial in the preoperative analysis [8]. Because endoscopic transsphenoidal surgery is gradually developing to reach the skull base, understanding of anatomical landmarks of the spinoid sinus is important [9]. Pre-operative CT For the surgical procedure, a thorough examination of all anatomical variants is required, with the number and position of inter-sinus septa being particularly important due to their close association with the Internal carotid artery [10]. Endoscopes have been introduced to do surgery beyond the paranasal sinuses in the past few years. Diseases related to the paranasal sinuses, Functional endoscopic sinus surgery (FESS) has widespread popularity in the treatment of benign, chronic inflammatory [11]. The transnasal endoscopic method can be used for lesions at the base of the skull base particularly lesions in the sella turcica because this method allows for great imaging of the pituitary gland and its surroundings while not a retraction of the brain, as well as lower down the rate of morbidity and mortality in comparison to the transcranial method [12]. The increased number of anatomical dissimilarities of the sphenoid sinus has increased the risk chances of the injury to important glandular and neurovascular structures. sphenoid sinus hiperpneumatization with following pneumatization of the ethmoid sinus has chances of injury to the optic nerve [13]. Because of the diversity in placements, quantities, and substitutions within the sinus septum, the internal carotid artery protrusion of the sinus lumen increases the risk of damage during endoscopic treatments [14]. A study carried out in 2004 reported that multiple septa in 82.5% of cases, while another study in 2004 claimed that multiple septa in 48% of cases [15,16], and Hamid et al., in 2008 reported that cases of multiple septa 10.9% [17]. Regardless of the various percentages of multiple septa, all scholars agreed that the insertion of these septa into the sphenoid walls is important. In our study, only one septum had 65 (66%) men and 35 (70.8%) women. The existence of more than one septum (multiple septa) was registered in (34 %) of males and 23%, of females which differs significantly from the results of the other studies. A study carried out in 2005 and 2006 evidenced septal insertion to the carotid canal in 25% of cases, and Abdullah et al 2011 reported their presence in 12% of cases. In this work, we

focused on implantation in the carotid canal's projection onto the posterolateral sinus wall [18,19]. In our study insertion of main or accessory septa to the carotid canal in 24 men, which makes 20.8% of patients. From this number, tying the carotid canal in men occurred in 24 men, accounting for 20.8 and 16 female patients (16.8%). In our research, we discovered that the main septum location is frequently not in the middle line, but rather on the left side or right side. The major septa cannot be used as a trustworthy marker during endoscopic treatments. In addition, when examining axial imaging, the medial-placed septum does not always suggest the whole extent of the medial line but rather howls laterally on its front or backsides. Furthermore, the implantation of the primary and secondary septa, both in the ocular canal, requires special care, and one of the objectives of our research was to investigate this area. The septum manipulation must be considered during transeptal sphenoidectomy, especially if a preoperative CT diagnosis considers its attachment to the carotid or optic canal walls [20]. There is a risk of damaging the surrounding structures.

## CONCLUSIONS

The septa of the sphenoid sinus are exceedingly diverse. The optimum approach for detecting and evaluating the architecture of the sphenoid sinus, especially for sinus anatomical alterations and sinus diseases is computed tomography. This information will allow for a very detailed look at the normal and abnormal changes that are needed for functional endoscopic sinus surgery to be successful.

## REFERENCES

- [1] Aijaz A, Khan N, Mubeen S and Rasheed B. Anatomical variations of human sphenoid sinus in terms of volume and septation pattern in a subset of Pakistani population using computed tomographic images. *Journal of the Pakistan Medical Association*. 2022;72(4):702-6. doi.org/10.47391/JPMA.3543.
- [2] Abdulghani YS and Salih KA. Sphenoidal Air Sinuses Septum Anatomical Variations among Sudanese-A Radiological Study. *Journal of Medical and Dental Science Research*. 2021;8(4):39-42.
- [3] Amusa YB, Eziyi JA, Akinlade O, Famurewa OC, Adewole SA and Nwoha PU et al. Volumetric measurements and anatomical variants of paranasal sinuses of Africans (Nigerians) using dry crania. *International journal of medicine and medical sciences*. 2011; 3(10): 399 - 03. doi.org/10.5897/IJMMS.9000254.
- [4] Yousef M, Sulieman A, Hassan H, Ayad C, Bushara L and Saeed A et al. Computed tomography evaluation of paranasal sinuses lesions. *Sudan Medical Monitor*. 2014;9(3):123. doi: 10.4103/1858-5000.149837.

- [5] Yazici D. The Analysis of Computed Tomography of Paranasal Sinuses in Nasal Septal Deviation. *J Craniofac Surg.* 2019;30(2):e143-e147. doi: 10.1097/SCS.00000000000005077.
- [6] Adil R, Qayyum A and Qayyum A. Correaltion of X rays and computed tomography in paranasal sinus diseases. *PAFMJ.* 2011 Sep 30;61(3).
- [7] Vincent TE and Gendeh BS. The association of concha bullosa and deviated nasal septum with chronic rhinosinusitis in functional endoscopic sinus surgery patients. *Med J Malaysia.* 2010;65(2):108-11.
- [8] Jaworek-Troć J, Zarzecki M, Zamojska I, Troć P, Chrzan R and Zawiliński J et al. The total number of septa and antra in the sphenoid sinuses: evaluation before the FESS. *Folia Medica Cracoviensia.* 2018;58(3). DOI: 10.24425/fmc.2018.125073.
- [9] Farhan N, Naqvi SU, Rasheed B, Sattar A, Khan M and Rahim A et al. Identification of Significant Anatomical Variations in the Nose and Anterior Skull Base Using Computed Tomography: A Cross-Sectional Study. *Cureus.* 2020;12(6):e8449. doi: 10.7759/cureus.8449.
- [10] Gibelli D, Cellina M, Gibelli S, Cappella A, Oliva AG and Termine G et al. Relationship between sphenoid sinus volume and accessory septations: A 3D assessment of risky anatomical variants for endoscopic surgery. *Anat Rec (Hoboken).* 2020;303(5):1300-1304. doi: 10.1002/ar.24245.
- [11] Fadda GL, Petrelli A, Urbanelli A, Castelnuovo P, Bignami M and Crosetti E et al. Risky anatomical variations of sphenoid sinus and surrounding structures in endoscopic sinus surgery. 2022. doi.org/10.21203/rs.3.rs-1519047/v1.
- [12] Raseman J, Guryildirim M, Beer-Furlan A, Jhaveri M, Tajudeen BA and Byrne RW et al. Preoperative Computed Tomography Imaging of the Sphenoid Sinus: Striving Towards Safe Transsphenoidal Surgery. *J Neurol Surg B Skull Base.* 2020;81(3):251-262. doi: 10.1055/s-0039-1691831.
- [13] DeLano MC, Fun FY and Zinreich SJ. Relationship of the optic nerve to the posterior paranasal sinuses: a CT anatomic study. *AJNR Am J Neuroradiol.* 1996;17(4):669-75.
- [14] Papadopoulou AM, Chrysikos D, Samolis A, Tsakotos G and Troupis T. Anatomical Variations of the Nasal Cavities and Paranasal Sinuses: A Systematic Review. *Cureus.* 2021;13(1):e12727. doi: 10.7759/cureus.12727.
- [15] Kantarci M, Karasen RM, Alper F, Onbas O, Okur A and Karaman A. Remarkable anatomic variations in paranasal sinus region and their clinical importance. *Eur J Radiol.* 2004;50(3):296-302. doi: 10.1016/j.ejrad.2003.08.012.
- [16] Idowu OE, Balogun BO and Okoli CA. Dimensions, septation, and pattern of pneumatization of the sphenoidal sinus. *Folia Morphol (Warsz).* 2009;68(4):228-32.
- [17] Hamid O, El Fiky L, Hassan O, Kotb A and El Fiky S. Anatomic Variations of the Sphenoid Sinus and Their Impact on Trans-sphenoid Pituitary Surgery. *Skull Base.* 2008;18(1):9-15. doi: 10.1055/s-2007-992764.
- [18] BADEMCİ G and Birsen ÜN. Surgical importance of neurovascular relationships of paranasal sinus region. *Turkish Neurosurgery.* 2005;15(2).
- [19] Unal B, Bademci G, Bilgili YK, Batay F and Avci E. Risky anatomic variations of sphenoid sinus for surgery. *Surg Radiol Anat.* 2006;28(2):195-201. doi: 10.1007/s00276-005-0073-9.
- [20] Kim D, Kim S, Pak MG and Bae WY. A Case of Small Cell Carcinoma Originated from Sphenoid Sinus in Patient with Recurrent Pituitary Tumor. *Journal of Rhinology.* 2021;28(2):110-5. doi.org/10.18787/jr.2021.00351.