



Original Article

Sonographic Evaluation, Prevalence and Differential Diagnosis of Renal Cyst

Sunaina Ali¹, Maniha Nauman¹, Minahil Saleem¹, Iqra Manzoor¹, Iqra Ramzan¹ and Mehreen Fatima¹¹University Institute of Radiological Sciences & Medical Imaging Technology, Faculty of Allied Health Sciences, The University of Lahore, Lahore, Pakistan

ARTICLE INFO

Key Words:

Renal cyst, prevalence, ultrasound, autosomal dominant polycystic kidney, simple cyst, complex cyst.

How to Cite:

Sunaina Ali, Maniha Nauman, Minahil Saleem, Ms. Iqra Manzoor, Dr. Iqra Ramzan, & Dr. Mehreen Fatima. (2022). Sonographic evaluation, prevalence and differential diagnosis of renal cyst : Sonographic evaluation, prevalence and differential diagnosis of renal cyst. Pakistan BioMedical Journal, 5(5). <https://doi.org/10.54393/pbmj.v5i5.426>

*Corresponding Author:

Sunaina Ali
University Institute of Radiological Sciences & Medical Imaging Technology, The University of Lahore, Lahore, Pakistan
sunainaali75@gmail.com

Received Date: 9th May, 2022

Acceptance Date: 24th May, 2022

Published Date: 31st May, 2022

ABSTRACT

Renal cysts are a common finding on routine ultrasound scans. Renal cysts are easily detected with ultrasound, with its low cost, non-invasiveness and no exposure to radiation, ultrasound is an exceptional method for primary evaluation of patients with cystic lesions. Most cysts detected by chance and are benign, but they can become complex if infection, bleeding, or ischemia occur. **Objective:** To assess the prevalence of renal cysts and find relationship with age and sex in the study group and to outline the differential diagnosis of renal cyst by ultrasonography. **Methods:** This was a cross-sectional descriptive study. An ultrasound examination was performed on 109 patients who were diagnosed with renal cysts. Cystic wall thickness, form, number of cysts, and acoustic enhancement were employed as sonographic criteria for evaluating renal cysts. **Results:** The incidence of renal cysts were more in females than in male (52.3% vs. 47.7%). The majority of the cysts were solitary than multiple (69.7% vs. 30.3%). Most of the cysts were at lower pole cortical cysts (22.9%). Simple cyst was the most common type (90.8%), autosomal-dominant polycystic kidney disease (ADPKD) was 6.4%. 59 patients were asymptomatic and 50 patients were symptomatic with flank pain as the most common symptom. **Conclusions:** Simple cysts are the most frequently found kidney cysts on ultrasound. Aging and hypertension were common risk factors related with renal cysts. End-stage renal failure is caused by ADPKD, which is the most prevalent genetic cause. Diagnosis and early detection of renal cyst is important, routine ultrasound scans for adults is advisable prior to getting any serious complication.

INTRODUCTION

Renal cysts are one of the most common ultrasonographic finding in kidneys [1]. It might be sporadic, hereditary, associated with advanced acquired cystic kidney disease (ACKD), or even malignant in rare cases [2]. Renal cyst is a pocket full of fluid collection in or on the kidneys. It is a fluid-filled sac that arises from the cortex and may distort the renal contour [3]. Even though, nearly all renal cysts are picked incidentally and without any symptoms, sometimes they become large enough to cause subtle flank pain and discomfort. Occurrence of renal cyst between birth and 20 years is rare but prevalence of renal cysts vary in accordance to sex and increases with age. It is more common in males than in females [4]. Renal cyst is

classified as "simple" or "complex", sonographic features of simple cyst include, thin wall, no internal septations or debris, absence of internal echoes, anechoic lumen, oval or spherical shaped with posterior wall enhancement. Wall thickening, uneven form, septations, calcifications, and nodularity are all signs of complexity [4,5]. Renal cysts are easily detected with ultrasound, most important strengths of ultrasound are to differentiate benign vs complex cyst and cysts vs solid lesions. With its low cost, noninvasiveness, and lesser radiation exposure with ultrasound it is an ideal method for primary evaluation of patients with cystic lesions [6]. Autosomal-dominant polycystic kidney disease (ADPKD) manifests in the third

decade of life, detection and assessment is necessary since it develops silently and may cause hypertension and renal failure [7]. On ultrasound, kidneys are bilaterally enlarged due to the development of thousands of cysts of varying sizes. The development of bilateral, multiple fluid-filled cysts is a primary feature of ADPKD [6,8]. By the age of 60 years, approximately half of the people with ADPKD have developed end-stage renal disease [9]. Acquired cystic disease can be easily differentiated from ADPKD by size of the kidneys which is smaller than normal among those with ACD whereas it could be extremely large in case of ADPKD [10]. Present study is to assess the prevalence of renal cysts and find its relationship with age and sex in the study group.

METHODS

This was a Cross-sectional descriptive study, patients who had gone through abdominal ultrasound scan and diagnosed with renal cysts were used for the study. Sample size was calculated at 95% level of confidence and 5 % margin of error. Following formula was used to calculate sample size. Total 109 individuals fulfilling the inclusion criteria was scanned. All adults from the age of 21 to old-age up to 90 years, population, with diagnosed renal cysts were considered as candidates for the study. Exclusion criteria were nephrectomy, unilateral kidney, congenital anomalies related to kidney. Toshiba ultrasound machines model number Xario – XG were used to scan patients in supine position, 3-5 MHz with curve-linear probe. It may be necessary to adjust the patient's position to obtain an acceptable acoustic window, depending on their body type and the location of the kidney cyst. Due to the possibility of bowel gas interfering with the scan, decubitus positioning is frequently essential. The imaging parameters were changed, as well as the machine settings (depth, overall gain and focus). The focal zone was centered on the region of interest and the highest achievable frequency was chosen. Coronal, transverse and sagittal planes were used to scan the kidneys to the complete shape and size. The probe was angled to capture the cyst and measure longitudinal and transverse diameters (in mm). A prepared data collecting sheet was used to collect demographic and clinical information, as well as the presence and criteria of the cyst. The number of cysts, site (lower, middle or upper pole of the kidney) and cyst size were recorded. In this study, SPSS software program version 21 was used to record and analyze the data. Qualitative variables like gender, symptomatic and asymptomatic, sign and symptoms, location of renal cyst was represented as frequencies and percentages. Quantitative variables like age and size of cyst and wall thickness were given in mean \pm

standard deviation. The study was approved by the hospital ethical committee and institutional Review Board of the university of Lahore. Patients gave informed consent after learning about the significance of the study and agreed to have their data used for research reasons. There were no names or IDs given, and all personal information was kept classified.

RESULTS

The study group consisted of 109 patients who were all diagnosed with renal cysts after being evaluated with ultrasonography. It was discovered that the frequency distribution of sex was as follows: female was higher than male, female 52.3% (n = 57) and male 47.7% (n = 52) with mean age of 49.95 years. Most of the patients were asymptomatic 59 (54.1%) and 50 patients (45.9%) were symptomatic, flank pain was seen in (33.0%), abdominal pain (4.6%), epigastric pain and lumbar pain (1.8%), back pain, melena, chest pain, burning micturition, drowsiness (0.9%). Table 1 summarizes the location of renal cyst, most of the cyst were lower pole cortical cyst (22.9%). Simple cyst was the most common type (90.8%). Majority of cysts were solitary (69.7%) whereas (30.3%) were multiple. Total number of simple cysts was (78.0%), incidence of polycystic kidney was (6.4%). Table 2 is a cross tabulation between age and sex which shows the prevalence of renal cysts by sex and age group. 3D bar chart shows the differential diagnosis and cyst criteria in males and females.

Variables	Frequency (%)
Lower pole cortical cyst	25(22.9)
Middle pole cortical cyst	14(12.8)
Upper pole cortical cyst	21(19.3)
Upper pole medullary cyst	10(9.2)
Lower pole medullary cyst	7(6.4)
Middle pole medullary cyst	7(6.4)
Middle pole milk of calcium cyst	1(0.9)
Bilateral renal cyst	17(15.6)
Polycystic kidney	7(6.4)
Total	109(100.0)

Table 1: Frequency distribution of location of renal cyst in the study population

Age of patients	Gender		Total
	Male	Female	
21 - 40	25	13	38
41 - 60	24	20	44
61 - 80	8	17	25
>81	0	2	2
Total	57	52	109

Table 2: Cross tabulation between age and sex

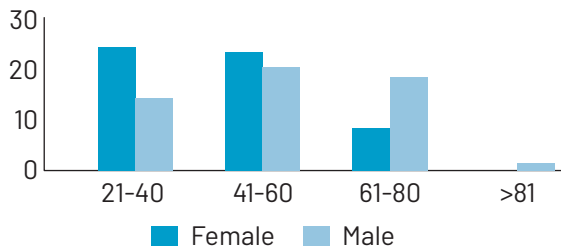


Figure 1: Graph showing cross tabulation between age and sex

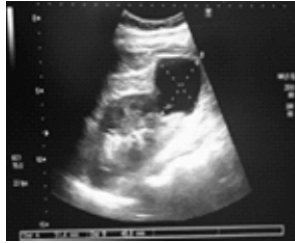

Figure 2: Simple cyst measuring 51.4 mm x 48.8 mm in a patient of 60 years at the lower pole of left kidney

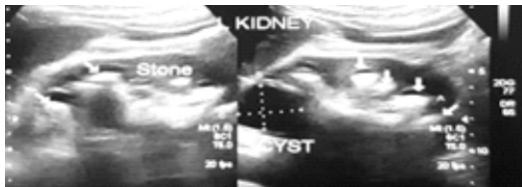

Figure 3: Showing renal stones with renal cyst in a patient of 62 years old

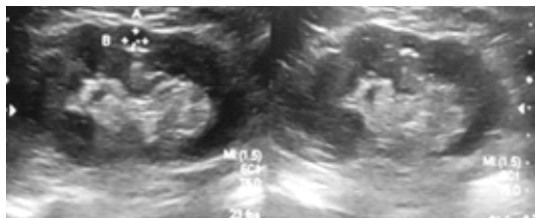

Figure 4: Showing milk of calcium cyst measuring 6.1 mm x 6.9 mm at the middle pole left kidney in a patient of 65 years old.

DISCUSSION

Renal cyst was evaluated and classified on their sonographic appearance by using ultrasound. The findings of this study demonstrated that cysts were prevalent among patients aged 41 to 60. This outcome is agreeing with Chang et al., who reported that the prevalence of renal cyst increases with age and it is common in 60s or later ages of life. This indicates that aging is a major risk factor for renal cyst development. Females were found to be more afflicted by renal cysts than males, according to the findings of this study (52.3% vs. 47.7%). The results contradict Chang et al findings, who figured out that a male-female ratio of 2.81 (15.14% vs. 5.38%) [11]. Ozveren et al., also concluded that kidney cysts were more common in men and the elderly, and that they were associated with

diabetes [12]. Renal cysts elicited more from the cortex than the medulla, according to the research. (55% vs. 22%) and the incidence of bilateral cyst is lesser than unilateral cyst (15.6% vs. 77.9%). Hong et al., studied the effect of simple renal cysts on hypertension and found that the location, size, and number of cysts were all critical factors in hypertension [13,14]. Hypertension has been associated to the presence of simple renal cysts [15]. The occurrence of solitary cysts were more than multiple cysts (69.7% vs. 30.3%). This finding supports Chang et al findings that the majority of renal cysts (82.3%) are solitary [11]. Cysts increases in size as the age advances, the prevalence of cysts is known to correspond with demographic factors, cysts are detected more in number and larger in size in older individuals [12]. Terada et al., found that cysts grow quicker in patients under 50 years old than in those 50 years or older, at 3.94 and 1.84 mm per year, respectively [16]. In the current study, simple cysts were more common 78%, complex cyst 3.7%. The incidence of Acquired dominant polycystic kidney disease (ADPKD) was 6.4%. These cysts are important because there is a significant link between hypertension and flank discomfort, which is a typical symptom in individuals with ADPKD, which is often detected late and difficult to control and manage [17]. Hypertension is a prevalent symptom in most cases with ADPKD, according to Chapman et al [18]. According to Miskulin et al [19], the initial indication of ADPKD is flank pain. This confirms our findings that flank pain was a common symptom. Cyst development and renal hypertrophy cause considerable flank pain. Early detection is important since renal failure is a common cause of death. The pathologies that associated with renal cysts included renal stones (4.6%), hydronephrosis (1.8%), medical renal disease (1.8%). Vascular abnormalities like aneurysms, pseudoaneurysms (PSAs), and arteriovenous malformations (AVMs) should also be reviewed in the differential diagnosis of cystic renal lesions. Arterial pathologies and renovascular connection with simple renal cyst can be coincident to age-related changes in renal ducts and tubules [12,20].

CONCLUSION

Simple cysts are the most frequent type of renal cysts, with cortical cysts accounting for the majority of the cysts. Females were more likely than males to have kidney cysts. Incidence of solitary cysts were found to be more common than multiple cysts. Renal cysts were linked to ageing and hypertension as prevalent risk factors. With more than half of patients requiring dialysis by the age of 60, ADPKD is the most common hereditary cause of end-stage renal failure. Ultrasound plays a significant role in evaluating and

classifying renal cysts, which helps in management and follow-up. Hence, the diagnosis and early detection of renal cyst is important, routine ultrasound scans for adults is advisable prior to getting any serious complications.

REFERENCES

- [1] Withey SJ, Verma H, Prezzi D. Multimodality Assessment of Cystic Renal Masses. Paper presented at: Seminars in Ultrasound, CT and MRI2020. doi.org/10.1053/j.sult.2020.05.001
- [2] Niyyar VD, O'Neill WC. Point-of-care ultrasound in the practice of nephrology. *Kidney International*. 2018;93(5):1052-1059. doi.org/10.1016/j.kint.2017.11.032
- [3] Sigmon DF, Shikhman R, JIN. Renal cyst. 2017.
- [4] Garfield K, Leslie SW. Simple renal cyst. StatPearls [Internet]. 2020.
- [5] Burgan CM, Sanyal R, Lockhart ME. Ultrasound of renal masses. *Radiologic Clinics*. 2019;57(3):585-600. doi.org/10.1016/j.rcl.2019.01.009
- [6] Ugwuanyi D, Chiegwu H, Anakwue A-M, Eze E. Ultrasonography Evaluation of Renal Cyst Disease in Nnewi Urban, South East Nigeria. *Asian Journal of Science and Technology*. 2017;08:5417-5421.
- [7] Gameraddin MB, Babiker MS. Renal cysts: Sonographic evaluation and classification in Sudanese adults. *Journal of Health Research and Reviews*. 2016;3(3):111. doi.org/10.4103/2394-2010.193181
- [8] Shiza ST, Guttikonda J. Exceptionally Large Kidneys in Autosomal Dominant Polycystic Disease in India. *Cureus*. 2021;13(3). doi.org/10.7759/cureus.13905
- [9] Harris PC, Torres VE. Polycystic kidney disease, autosomal dominant. *GeneReviews*® [Internet] 2018.
- [10] Chapman AB, Rahbari-Oskoui FF, Bennett W. Acquired cystic disease of the kidney in adults. *UpToDate* version. 2011;15.
- [11] Chang C-C, Kuo J-Y, Chan W-L, Chen K-K, Chang LS. Prevalence and clinical characteristics of simple renal cyst. *Journal of the Chinese Medical Association*. 2007;70(11):486-491. doi.org/10.1016/S1726-4901(08)70046-7
- [12] Ozveren B, Onganer E, Türkeri LN. Simple renal cysts: prevalence, associated risk factors and follow-up in a health screening cohort. *Urology journal*. 2016;13(1):2569-2575.
- [13] Chin HJ, Ro H, Lee HJ, Na KY, Chae D-W. The clinical significances of simple renal cyst: Is it related to hypertension or renal dysfunction? *Kidney international*. 2006;70(8):1468-1473. doi.org/10.1038/sj.ki.5001784
- [14] Hong S, Lim J, Jeong I, Choe J, Kim C, Hong J. What association exists between hypertension and simple renal cyst in a screened population? *Journal of human hypertension*. 2013;27(9):539-544. doi.org/10.1038/jhh.2013.12
- [15] Kong X, Ma X, Zhang C, Su H, Gong X, Xu D. Increased risk of kidney damage among Chinese adults with simple renal cyst. *International urology and nephrology*. 2018;50(9):1687-1694. doi.org/10.1007/s11255-018-1880-3
- [16] Terada N, Ichioka K, Matsuta Y, Okubo K, Yoshimura K, Arai Y. The natural history of simple renal cysts. *The Journal of urology*. 2002;167(1):21-23. doi.org/10.1016/S0022-5347(05)65373-6
- [17] Tellman MW, Bahler CD, Shumate AM, Bacallao RL, Sundaram CP. Management of pain in autosomal dominant polycystic kidney disease and anatomy of renal innervation. *The Journal of urology*. 2015;193(5):1470-1478. doi.org/10.1016/j.juro.2014.10.124
- [18] Chapman AB, Stepniakowski K, Rahbari-Oskoui F. Hypertension in autosomal dominant polycystic kidney disease. *Advances in chronic kidney disease*. 2010;17(2):153-163. doi.org/10.1053/j.ackd.2010.01.001
- [19] Miskulin DC, Abebe KZ, Chapman AB, et al. Health-related quality of life in patients with autosomal dominant polycystic kidney disease and CKD stages 1-4: a cross-sectional study. *American journal of kidney diseases*. 2014;63(2):214-226. doi.org/10.1053/j.ajkd.2013.08.017
- [20] Ziganshin BA, Theodoropoulos P, Salloum MN, et al. Simple renal cysts as markers of thoracic aortic disease. *Journal of the American Heart Association*. 2016;5(1):e002248. doi.org/10.1161/JAHA.115.002248.