



Original Article



Subcentimeter Ureteric Calculi on Plain Computed Tomography KUB in Patients Presenting with Renal Colic

Tayyaba Tahira¹, Yasser Khan¹, Zobia Saleem^{*}, Asim Raza¹, and Aqsa Aslam¹¹School of Allied Health Sciences, Combined Military Hospital, Lahore Medical College and Institute of Dentistry, Lahore, Pakistan

ARTICLE INFO

Keywords:

Subcentimeter Ureteric Calculi, Renal Colic, Pain Distribution

How to Cite:Tahira, T., Khan, Y., Saleem, Z., Raza, A., & Aslam, A. (2025). Subcentimeter Ureteric Calculi on Plain Computed Tomography KUB in Patients Presenting with Renal Colic: Subcentimeter Ureteric Stone Detection. *Pakistan BioMedical Journal*, 8(4), 11-16. <https://doi.org/10.54393/pbmj.v8i4.1224>***Corresponding Author:**

Zobia Saleem

Department of Allied Health Sciences, Combined Military Hospital, Lahore Medical College and Institute of Dentistry, Lahore, Pakistan
zobiasaleem95.work@gmail.comReceived date: 20th February, 2025Revised date: 31st March, 2025Acceptance date: 9th April, 2025Published date: 30th April, 2025

ABSTRACT

Renal colic, often caused by ureteric stones, is a common and painful condition. Subcentimeter ureteric stones are frequently identified using CT KUB. Understanding the demographics, pain levels, and distribution of these stones can help in better diagnosing, managing and treating the condition. **Objective:** To determine the prevalence of subcentimeter ureteric calculi in patients who have renal colic. **Methods:** Between September and December of 2024, a four-month descriptive cross-sectional study was carried out at the Diagnostic Center of CMH, Lahore. The target population included all patients presenting with renal colic, undergoing CT KUB. Sample size of 266 was calculated using WHO calculator and Cochran's formula. Data were collected using proforma and CT KUB reports, and analyzed using IBM SPSS version 26.0. 95% confidence intervals were provided for the results, and statistical tests including the Kruskal-Wallis, Shapiro-Wilk, Mann-Whitney U, and Normality tests were employed. Findings: Patients ranged in age from 18 to 71 years old, with an average age of 43. **Results:** The majority of patients were between the ages of 20 and 35, with more men (59.8%) than women (40.2%). Pain levels varied, with an average of 5.36 on the visual analog scale. Moderate pain was the most common, experienced by 38.33% of patients. Intermittent pain was more common (68.8%) than continuous pain (31.2%). Dysuria was the most common urination issue (35.71%). Ureteric stones were present in 77.82% of patients, with the right and left renal locations being the most common sites. The most common type of stones found were subcentimeters (60.9%). **Conclusions:** The distribution of subcentimeter ureteric stones and pain levels in patients with renal colic are described in this study on the identification of ureteric calculi in patients presenting with renal colic on CT KUB. The findings mostly seen in middle aged male patients with intermittent pain, right and left renal calculus were the most common sites and subcentimeter ureteric calculi were frequently observed category. Also describes the other findings like Hydronephrosis, cyst, and peripheral fat.

INTRODUCTION

Ureteric calculi is the formation of stones present in the ureter. It is found that these stones contain mainly calcium in about 80%. Ureteric calculi is one of the most frequently diagnosed urologic diseases worldwide. It is estimated that there will be a 12% lifetime incidence of the disease, usually occurring in patients aged 20 to 50 years [1, 2]. Acute flank discomfort brought on by renal colic is a typical clinical presentation in the accident and emergency room. Renal colic patients usually have radiating, intense flank discomfort that is colicky, either with or without hematuria. To evaluate patients with acute renal colic pain, two imaging modalities are used: computed tomography (KUB),

ultrasound, and standard radiography of the kidneys, ureters, and bladder [3, 4]. It is now possible to reliably diagnose ureteral calculi on plain computed tomography CT KUB because to technological advancements [5]. Conventional abdominal radiography of the kidney, ureter, and bladder (KUB) is less sensitive than CT KUB in detecting subcentimeter ureteral calculi because small ureteral calculi are invisible on ultrasonography or abdominal radiography. Therefore, many patients who come with flank pain first have plain CT KUB in order to diagnose subcentimeter ureteral calculi [6]. Renal colic pain can be caused by a number of reasons, including pressure from



the proximal stone, inflammation and edema surrounding the stone, smooth muscle spasms in the ureter, kidney stone restriction of urine flow, and elevated pressure on the urinary tract wall. The primary mechanisms of pain in these patients are urethral smooth muscle contractions and increased pressure in the urinary system as a result of an increase in local blood flow. Furthermore, there is heightened pain sensitivity. Tension in the renal pelvis initiates prostaglandin synthesis, production, and local release. Vasodilation and diuresis result from this, increasing intrarenal pressure. The ureter has a limited channel, and measuring its diameter can provide information about its status, particularly in relation to obstructive pathologies caused by compressive abdominal mass, ureterolithiasis, congenital aetiologies, or any other distal blockage. Long-term blockage may result in hydronephrosis and consequent kidney injury. Accurately diagnosing ureteral dilatation is essential for patient care, particularly in situations of low-density stones, periureteral calcifications, small non-obstructive stones, ureteral calculi, and surrounding inflammations that are mild or borderline [7]. Many research articles have limited literature on subcentimeter ureteral calculi in Pakistan however much of the literature is present in patients with plain CT KUB reporting on renal calculi and patients with suspected ureteral calculi with a history of renal colic pain. This study will contribute to improve patient outcomes in the diagnosis, prognosis and treatment of disease, reduces the risk of further complications and lessen patient sufferings.

Ureteric calculi, particularly subcentimeter stones, are a common cause of renal colic and require accurate and timely diagnosis for effective management. Although CT KUB is considered the gold standard for detection, there is limited local evidence in Pakistan regarding the prevalence, size distribution, and clinical presentation of subcentimeter ureteric calculi. Most existing studies focus on general urolithiasis without specifically addressing small-sized stones and their associated pain characteristics. This study aims to determine the prevalence of subcentimeter ureteric calculi, assess their distribution and clinical presentation in patients with renal colic, and provide evidence to support improved diagnostic and management strategies using CT KUB.

METHODS

This study was descriptive cross-sectional was conducted in Diagnostic Center at Combined Military Hospital (CMH), Lahore. The trial ran for six months, from July to December 2024. The prevalence of ureteric calculi was 53% in study conducted by F G Sommer FG et al [8]. WHO calculator and Cochran, W. G. (1997) formula was used to calculate the

sample size (n=266)[9]. Purposive sampling technique was used to gather the data. All patients with the history of renal colic, Participants in this study had to be at least 18 years old and be visiting the diagnostic center for CT KUB. Patients with Double J (DJ) stents (stents inserted in the ureters) were excluded, pregnant females and operated cases (all patients with history of any previously performed renal surgery between 5 years). Computed Tomography (Siemens 64 slice CT) was used to perform CT KUB. Every patient who presented with renal colic gave their written informed permission. All data and information, were kept private. Throughout the trial, patients' identities were kept anonymous. This study was carried out in compliance with the Declaration of Helsinki (Case# 87/ERC/CMH/LMC) and the ethical guidelines established by the CMH LMC and IOD ethical committees. Participants in the study had their rights upheld. Prior to examination, each patient gave their assent. Data were collected from the Diagnostic Center at CMH, Lahore, using CT KUB reports of patients with renal colic and a standardized proforma. Pain was assessed using the Visual Analogue Scale (VAS) and categorized as mild (1-3), moderate (4-6), and severe (7-10). In order to identify and measure ureteric calculi, with an emphasis on subcentimeter stones, patients received plain CT KUB in a supine posture with their arms up. This procedure involved many slices. Stones were classified according to size as subcentimeter or larger. IBM SPSS version 26.0 was used to analyze the data, and both qualitative and quantitative descriptive statistics were calculated at a 95% confidence interval ($p < 0.05$). For comparisons of gender and age groups, the Mann-Whitney U and Kruskal-Wallis tests were used, while the Shapiro-Wilk and Kolmogorov-Smirnov tests were used as normality checks.

RESULTS

This study was conducted among 266 patients presenting with renal colic. The results shows the age of patients, pain intensity, frequency of ureteric calculi, their sizes and locations. The data were analyzed using basic statistical methods. Table 1 shows the majority of participants were male (59.8%), while females accounted for 40.2%. Age groups ranged widely, with the highest proportion of participants (35.7%) aged between 20-35 years, followed by those aged 51-65 years (31.6%). The patients were 43.42 years old on average, with a standard deviation of 15.017.

Table 1: Demographics Characteristics of Study Population (n = 266)

Characteristics	Categories (Mean \pm SD)	Frequency (%)
Gender	Male	159 (59.8%)
	Female	107 (40.2%)
Age Group of Patient (Years)	<20	4 (1.5%)
	20-35	95 (35.7%)
	36-50	64 (24.1%)

	51-65	84 (31.6%)
	>65	19 (7.1%)
Age of patients (Years)	43.42 ± 15.017	

Figure 1 shows the presence of ureteric calculi in patients. In 207 (77.8%) patients' ureteric calculi is present and in 59 (22.2%) patients' ureteric calculi is absent.

Presence of ureteric calculi

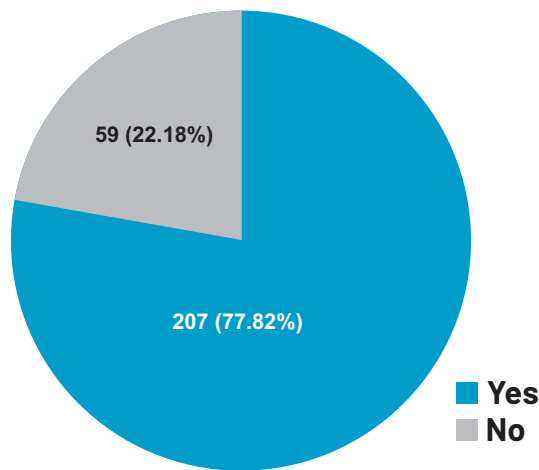


Figure 1: Presence of Ureteric Calculi in Patients

Table 2 shows the most common sites were the absence of calculi (22.2%), right renal calculi (21.8%), and left renal calculi (18.4%), with less frequent occurrences in other locations, such as right PUJ (4.1%) and bilateral ureteric calculus (0.4%). The majority of patients had one calculus (42.1%), followed by three or more calculi (22.6%), while 22.2% had no calculi detected. Regarding size, subcentimeter calculi were the most prevalent category (60.9%), with 16.9% categorized as above subcentimeter and 22.19% showing no calculi.

Table 2: Frequency Distribution of Ureteric Calculi by Site, Number, and Size Category among the Study Population (n=266)

Characteristics	Categories	Frequency (%)
Site of Ureteric Calculi	No Calculus	59 (22.2%)
	Left Renal Calculus	49 (18.4%)
	Right Renal Calculus	58 (21.8%)
	Left Ureteric Calculus	19 (7.1%)
	Right Ureteric Calculus	30 (11.3%)
	Left PUJ	1 (0.4%)
	Right PUJ	11 (4.1%)
	Left VUJ	14 (5.3%)
	Right VUJ	15 (5.6%)
	Bilateral Renal Calculus	9 (3.4%)
Bilateral Ureteric Calculus	1 (0.4%)	
Number of Ureteric Calculi	0	59 (22.2%)
	1	112 (42.1%)
	2	35 (13.2%)
	3 or above	60 (22.6%)

Ureteric Calculi Category	Absent	59 (22.19%)
	Subcentimeter	162 (60.9%)
	Above Subcentimeter	45 (16.9%)

Figure 2 shows ureteric calculi categories as 162 (60.9%) patients had subcentimeter calculi, while 59 (22.19%) had no ureteric calculi. Furthermore, 45 people (16.9%) had calculi that were above centimeter.

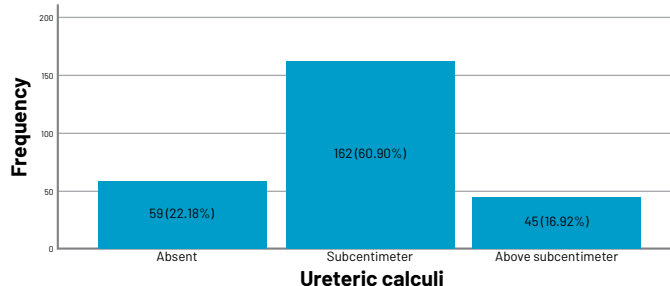


Figure 2: The distribution of Ureteric Calculi Shows a Significant Prevalence of different Categories

Figure 3 displays the size of ureteric calculi in individuals with renal colic on CT KUB by age group. The majority of stones are subcentimeter, while some larger ones are occasionally observed, particularly in the age ranges of 20–35 and 51–65. With a p-value of 0.141 from the Kruskal-Wallis test, there appears to be no discernible variation in stone size among age groups.

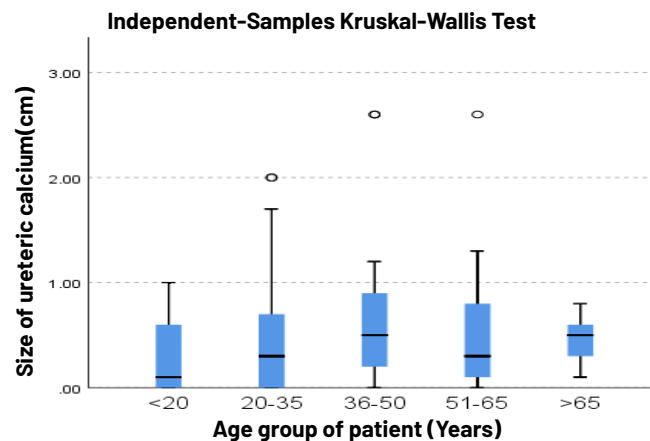


Figure 3: Association of the Size of Ureteric Calculi across different Age Groups

Figure 4 displays the outcomes of the Independent-Samples Mann-Whitney U Test. The mean rank of 107 girls in the sample is slightly higher (143.34) than that of 159 males (126.88). In contrast to female calculi, which are more likely to be smaller (1.0–2.0 cm), male calculi are more likely to be larger (2.0–3.0 cm). The level of significance is set at 0.050. The size of ureteric calculi does not differ statistically significantly across genders, according to the derived p-value of 0.085.

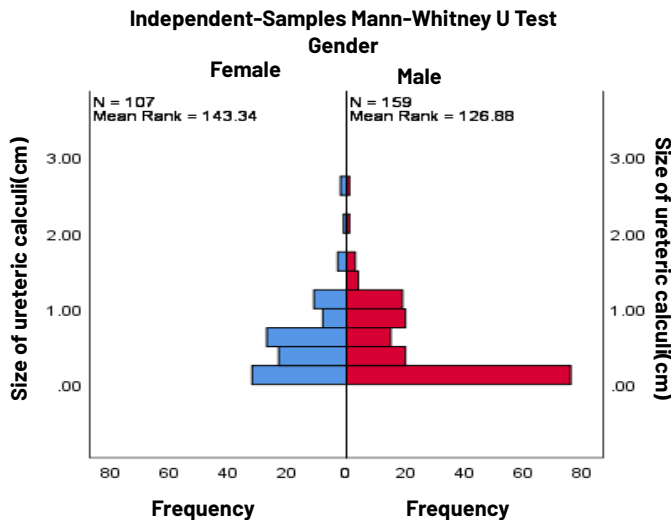


Figure 4: Association of Ureteric Calculi Size across Gender Categories

DISCUSSION

The current study reveals that the majority of 95 patients are between the ages of 20 and 35 years old (37.5%) as the age range of patients was 18-71 years old. The age group of 51-65 years old (31.6%), which has 85 patients, comes next. The age group of 36-50 years old (26.1%), which has 64 patients, comes next. According to this distribution, there are more patients in the younger age groups, especially those between 20 and 35. The distribution of patients by gender was the majority of 59.8% are (159) male and 40.2% are (107) female. These findings align with previous research, Chand RB *et al.*, was study conducted in June 2013. Gender and stone location outcome indicators were used in the prospective analysis of the data. The male to female ratio was 1.35:1, with 138 of the 240 cases being male and 102 being female. They were 9 to 83 years old. 187 patients, or 71.9% of the 240 total, were in the productive age range of 20 to 60 years. There were 345 urinary calculi in all, 208 of which were discovered in male patients and 137 in female patients. Six of the 345 calculi were in the bladder, 237 were renal stones, 47 were ureteric stones, 22 were in the Pelviureteric Junction (PUJ), and 33 were in the Vesicoureteric Junction (VUJ) [10]. The current research data show that these calculi are most frequently found in the size range of 0.3 to 0.4 cm, high frequency in this group. Most of the calculi are subcentimeter, and varying frequencies have been found in 0.1-0.2 cm and 0.2-0.3 cm size ranges. Furthermore, although their precise frequency surpasses the size of the chart, there are calculi greater than 1 cm. Medical practitioners can use this information to help choose the best course of therapy because it helps them understand the normal diameters of ureteric calculi. The study of Jeevaraman S *et al.*, in 2016 revealed some relative results in India. The age group of 21 to 49 years old had the highest incidence of ureteric calculi

(60%) among the 100 participants in the research. The biggest stone measured 13 mm. For 39 in patients (39%) medical management was used. 18 patients had stones that were no larger than 5 mm. smallest stone was 4mm shown in study. Forty of the 41 patients who had retrograde ureteroscopy had their stones successfully removed. 21 patients (21%) had ureterolithotomy and pyelolithotomy, two open surgical procedures [11]. The current study demonstrates that there is a considerable variance in the frequency distribution of ureteric calculi across different urinary tract sites. Of the patients, the majority, 112 people (41.3%), had one ureteric calculus, whereas 59 people (21.8%) have none. Furthermore, 60 patients (22.5%) had three or more calculi, while 35 patients (13.6%) had two calculi. According to this data, instances with one ureteric calculus are the most common presentation, followed by those with three or more calculi. While the study performed by Yap WW *et al.*, in 2014, 201 patients' 203 ureteric calculi were examined. Scout radiography's total sensitivity was 42.3% for Observer A and 52.2% for Observer B, with an interobserver reliability κ -value of 0.78. Two groups of patients with and without visible stones were compared in terms of mean Hounsfield units and size; both variables had p-values less than 0.0001, which indicates statistical significance. The study found that calculi larger than 4 mm in the upper ureter are more likely to be visible on scout radiography [12]. In emergency urological care, the assessment of renal colic is still crucial, and imaging is essential for both diagnosis and therapy planning. The gold standard for identifying ureteric calculi, particularly those smaller than 1 cm, is non-contrast computed tomography of the kidneys, ureters, and bladder (CT KUB). When compared to traditional imaging, Chowdhury FU *et al.*, showed that unenhanced multidetector CT offers high sensitivity and specificity for the identification of ureteric stones, greatly increasing the diagnostic accuracy in cases with acute renal colic [1]. Similarly, Ekici and Sinanoglu, found that CT significantly outperformed combined ultrasonography and radiography in stone detection and localization [2]. The timeliness and efficacy of CT KUB have also been explored. Rekant EM *et al.*, and Haddad MC *et al.*, emphasized that CT not only reduces the time to diagnosis but also improves outcomes by facilitating prompt treatment decisions [3, 4]. According to Huang CC *et al.*'s investigation, subcentimeter ureteric stones are still not very visible on scout radiographs, which supports CT's position as the preferred imaging modality [5]. The growing dependence on sophisticated imaging techniques like CT is further highlighted by recent epidemiological changes in the treatment of urinary tract calculi, as documented by Ghani KR *et al.* [6]. Additionally, studies like that of Itanyi UD *et al.*, offer anatomical insights, such as ureteric diameter measurements on CT, which aid in predicting stone

passage and potential obstruction [7]. Technological advancements, including reformatting and low-dose CT protocols, have improved the detection rates for subcentimeter stones, as supported by Sommer FG *et al* [8]. This is particularly relevant in younger patients and recurrent stone formers, where radiation exposure is a concern. Several large-cohort studies have investigated the most common sites of stone impaction. Chand RB *et al.*, and Jeevaraman S *et al.*, observed that the Ureterovesical Junction (UVJ) and Pelviureteric Junction (PUJ) are frequent sites for smaller stone lodging [10, 11]. These findings support the use of focused CT assessments in suspected cases of distal obstruction. Newer literature supports the scout radiograph's limited sensitivity, as explored by Yap WW *et al.*, who concluded that CT should not be replaced by KUB radiographs, especially when evaluating small-caliber stones [12]. Meanwhile, Brisbane W *et al.*, and Dyer RB *et al.*, further refined the classification of stone visibility and its relation to size, density, and location [13, 14]. The advent of risk stratification models and clinical scoring tools, such as those developed by Smith RC *et al.*, provide a framework to guide clinicians in selecting patients who may benefit from early CT KUB imaging [15]. Additionally, Miller and Kane's work on time-to-stone passage in observation cases supports CT findings as predictors for spontaneous expulsion [16]. Catalano and Dalrymple expanded on the diagnostic capabilities of CT urography in characterizing urinary tract anatomy and pathology, reinforcing CT's multifunctional diagnostic role [17, 18]. Lastly, there is strong evidence that CT is more accurate than IVU, especially for patients with subcentimeter calculi and non-classic presentations of renal colic, according to Vieweg J *et al.*, and Smith RC *et al.* [19, 20].

This study is limited by its single-center design and use of purposive sampling, which may affect the generalizability of findings. The cross-sectional nature also prevents establishing causal relationships. Additionally, potential confounders such as dietary habits, hydration status, and comorbidities were not controlled. Future research should involve multi-center studies with larger, more diverse populations and consider longitudinal designs to evaluate outcomes and recurrence. Further studies should also include risk factor analysis and comparison with other imaging modalities to strengthen clinical applicability.

CONCLUSIONS

The location of subcentimeter ureteric stones and pain levels in patients with renal colic are described in this study on the identification of ureteric calculi in patients presenting with renal colic on CT KUB. The findings mostly seen in middle aged male patients with intermittent pain, right and left renal calculus were the most common sites

and subcentimeter ureteric calculi were frequently observed category. Also describes the other findings like hydronephrosis, cyst, and peripheral fat. Multi-center research can enhance the quality of data in ureteric calculi studies by increasing the sample size. Future studies should control for confounding factors like chronic kidney disease and renal parenchymal disease to ensure more accurate results.

Authors' Contribution

Conceptualization: TT, ZS

Methodology: TT, ZS, YK, AR, AA

Formal analysis: TT, ZS, YK, AR

Writing and Drafting: TT, ZS, YK, AR

Review and Editing: TT, ZS, YK, AR, AA

All authors approved the final manuscript and take responsibility for the integrity of the work.

Conflicts of Interest

The authors declare no conflict of interest.

Source of Funding

The author received no financial support for the research, authorship and/or publication of this article.

REFERENCES

- [1] Chowdhury FU, Kotwal S, Raghunathan G, Wah TM, Joyce A, Irving HC. Unenhanced multidetector CT (CT KUB) in the initial imaging of suspected acute renal colic: evaluating a new service. *Clinical Radiology*. 2007 Oct; 62(10): 970-7. doi: 10.1016/j.crad.2007.04.016.
- [2] Ekici S and Sinanoglu O. Comparison of conventional radiography combined with ultrasonography versus nonenhanced helical computed tomography in evaluation of patients with renal colic. *Urological Research*. 2012 Oct; 40: 543-7. doi: 10.1007/s00240-012-0460-8.
- [3] Rekant EM, Gibert CL, Counselman FL. Emergency department time for evaluation of patients discharged with a diagnosis of renal colic: unenhanced helical computed tomography versus intravenous urography. *The Journal of Emergency Medicine*. 2001 Nov; 21(4): 371-4. doi: 10.1016/S0736-4679(01)00376-6.
- [4] Haddad MC, Sharif HS, Shahed MS, Mutaieri MA, Samihan AM, Sammak BM *et al.* Renal colic: diagnosis and outcome. *Radiology*. 1992 Jul; 184(1): 83-8. doi: 10.1148/radiology.184.1.1609107.
- [5] Huang CC, Chuang CK, Wong YC, Wang LJ, Wu CH. Useful prediction of ureteral calculi visibility on abdominal radiographs based on calculi characteristics on unenhanced helical CT and CT scout radiographs. *International Journal of Clinical*

- Practice. 2009 Feb; 63(2): 292-8. doi: 10.1111/j.1742-1241.2008.01861.x.
- [6] Ghani KR, Sammon JD, Karakiewicz PI, Sun M, Bhojani N, Sukumar S et al. Trends in surgery for upper urinary tract calculi in the USA using the Nationwide Inpatient Sample: 1999-2009. *Bob Jones University International*. 2013 Jul; 112(2). doi: 10.1111/bju.12059.
- [7] Itanyi UD, Aiyekomogbon JO, Uduma FU, Evinemi MA. Assessment of ureteric diameter using contrast-enhanced helical abdominal computed tomography. *African Journal of Urology*. 2020 Dec; 26: 1-5. doi: 10.1186/s12301-020-00021-0.
- [8] Sommer FG, Jeffrey Jr RB, Rubin GD, Napel S, Rimmer SA, Benford J et al. Detection of ureteral calculi in patients with suspected renal colic: value of reformatted noncontrast helical CT. *AJR. American Journal of Roentgenology*. 1995 Sep; 165(3): 509-13. doi: 10.2214/ajr.165.3.7645461.
- [9] Cochran WG. *Sampling Techniques*. John Wiley & Sons; 1977.
- [10] Chand RB, Shah AK, Pant DK, Paudel S. Common site of urinary calculi in kidney, ureter and bladder region. *Nepal Medical College Journal*. 2013 Mar; 15(1): 5-7.
- [11] Jeevaraman S, Selvaraj J, Niyamathullah NM. A study on ureteric calculi. *Journal of International Medical Research*. 2016 Oct; 3(10): 2969-72.
- [12] Yap WW, Belfield JC, Bhatnagar P, Kennish S, Wah TM. Evaluation of the sensitivity of scout radiographs on unenhanced helical CT in identifying ureteric calculi: a large UK tertiary referral centre experience. *The British Journal of Radiology*. 2012 Jun; 85(1014): 800-6. doi: 10.1259/bjr/64356303.
- [13] Dyer RB, Chen MY, Zagoria RJ. Abnormal calcifications in the urinary tract. *Radiographics*. 1998 Nov-Dec; 18(6): 1405-24. doi: 10.1148/radiographics.18.6.9821191.
- [14] Brisbane W, Bailey MR, Sorensen MD. An overview of kidney stone imaging techniques. *Nature Reviews Urology*. 2016 Nov; 13(11): 654-62. doi: 10.1038/nrurol.2016.154.
- [15] Smith RC, Verga M, McCarthy S, Rosenfield AT. Diagnosis of acute flank pain: value of unenhanced helical CT. *American Journal of Roentgenology*. 1996 May; 166(5): 97-101. doi: 10.2214/ajr.166.5.8610553.
- [16] Miller OF and Kane CJ. Time to stone passage for observed ureteral calculi: a guide for patient education. *Journal of Urology*. 1999 Mar; 161(3): 920-2. doi: 10.1016/S0022-5347(01)63865-3.
- [17] Catalano O. Computed tomography urography: an overview. *European Radiology*. 2001 Jan; 11(2): 355-65. doi: 10.1007/s003300000598.
- [18] Dalrymple NC, Verga M, Anderson KR, Bove P, Covey AM, Rosenfield AT et al. The value of unenhanced helical computerized tomography in the management of acute flank pain. *Journal of Urology*. 1998 Mar; 159(3): 735-40. doi: 10.1016/S0022-5347(01)63713-1.
- [19] Vieweg J, Teh C, Freed K, Leder RA, Smith RH, Nelson RH. Unenhanced helical computerized tomography for the evaluation of patients with acute flank pain. *Journal of Urology*. 1998 Mar; 159(3): 735-40. doi: 10.1016/S0022-5347(01)63713-1.
- [20] Smith RC, Rosenfield AT, Choe KA, et al. Acute flank pain: comparison of non-contrast-enhanced CT and intravenous urography. *Radiology*. 1995 Apr; 194(1): 789-94. doi: 10.1148/radiology.194.3.7862995.