



## Original Article



## Prevalence of Ovarian Cyst Diagnosed on Ultrasonography in Females of Reproductive Age Visiting Tertiary Care Hospital

Tashfeen Eman<sup>1</sup>, Fatima Batool<sup>1</sup>, Yasser Khan<sup>1</sup>, Filza Sultan<sup>1</sup>, Ramsha Asghar<sup>1</sup>, Asm Raza<sup>1</sup> and Zoha Ali<sup>1</sup><sup>1</sup>School of Allied Health Sciences, Combined Military Hospital, Lahore Medical College and Institute of Dentistry, Lahore, Pakistan

## ARTICLE INFO

## Keywords:

Ovarian Cyst, Ultrasonography, Reproductive Age, Abdominal Pain

## How to Cite:

Eman, T., Batool, F., Khan, Y., Sultan, F., Asghar, R., Raza, A., & Ali, Z. (2024). Prevalence of Ovarian Cyst Diagnosed on Ultrasonography in Females of Reproductive Age Visiting Tertiary Care Hospital: Prevalence of Ovarian Cyst. Pakistan BioMedical Journal, 7(12), 25-29. <https://doi.org/10.54393/pbmj.v7i12.1235>

## \*Corresponding Author:

Tashfeen Eman

School of Allied Health Sciences, Combined Military Hospital, Lahore Medical College and Institute of Dentistry, Lahore, Pakistan  
feman6193@gmail.comReceived Date: 2<sup>nd</sup> November, 2024Acceptance Date: 27<sup>th</sup> December, 2024Published Date: 31<sup>st</sup> December, 2024

## ABSTRACT

Ovarian cyst is most common in females of reproductive age ranging from 18-44 years. An ovarian cyst can cause many complications e.g. ovarian cyst accidents include cyst rupture, hemorrhage, and torsion thus timely diagnosis and treatment are important to lessen patient suffering. **Objective:** To calculate the prevalence of ovarian cyst diagnosed on ultrasonography in females of reproductive age visiting tertiary care hospital. **Methods:** This descriptive study was conducted in the radiology department of CMH Lahore Hospital from September to December 2023. All the individuals who fulfilled the inclusion/exclusion criteria were enrolled. A detailed history was taken from all patients including age, difficulty urination, pregnancy, pain and associated symptoms. Data entry and analysis were done by SPSS version 26. **Results:** The mean age was 30.25 years. All females were of reproductive age. Abdominal pain was the most common symptom in this study 52.1% (113). The second most common symptom discovered was irregular periods in which the frequency of female patients was 65 (30%). There were 217 females in this study. Out of 217, 137 (63.1%) were normal and 80 (36.9%) had ovarian cyst. So according to this study prevalence was 36.9%. **Conclusions:** Ultrasound is an effective, non-invasive and Radiation safe modality for the diagnosis and detection of prevalence of ovarian cysts in females of reproductive age. The most common symptom in females was abdominal pain and irregular periods. Ovarian cysts were present in one-third of the target population. The frequency of benign cysts was higher than malignant cysts.

## INTRODUCTION

A fluid-filled sac of ovaries known as an ovarian cyst can form when a follicle fails to release an egg. Premenopausal and postmenopausal women are predicted to have an ovarian cyst prevalence of 8% to 18%, which varies greatly from the overall population [1]. Simple cyst is widespread in premenopausal women, with follicles and corpus luteal cysts being the most common [2]. An ovarian cyst may be discovered by chance, during imaging prompted by symptoms, or after a pelvic mass was discovered during evaluation. Common types of adnexal cysts are dermoid cysts, simple cysts, endometriomas and hemorrhagic cysts. Other adnexal cysts that could be present are follicular cysts, corpus luteum cysts and mucinous cystadenoma, serous cystadenocarcinoma, mucinous

cystadenocarcinoma, para tubal cysts, granuloma, hydrosalpinx, ectopic, theca lutein cyst are common among post-menopausal women [3]. Dermoid cysts, one of the most prevalent benign ovarian tumors, are said to occur up to 20% of the time. They show up on a bilateral basis 10%-15% of the time [4]. Dermoid cysts are the most frequent ovarian tumors that appear during pregnancy, usually in the second trimester [5]. In premenopausal women, the overall incidence of a malignant ovarian cyst is roughly 1-3 per 1000 [6]. With a prevalence of 0.2% to 2%, big ovarian cysts are uncommon during pregnancy, while corpus luteum and theca-lutein cysts typically heal on their own between 14 and 16 weeks of gestation [7]. One-sided, free-moving, cystic, well-defined, and ascites-free ovarian



cysts are more likely to be benign. Conversely, bilateral malignant ovarian tumors with firm consistency, ill-defined margins, and ascites were discovered. Because ovarian tumors are invisible until they reach a specific size [8]. Ovarian benign, ovarian malignant, non-ovarian, gynecological, non-ovarian non-gynecological, and a further subgroup of pregnancy-specific diseases are all included in the aetiological classification. The first-line imaging technique for assessing adnexal masses is ultrasound [9]. All ovarian cysts have a 24% frequency of endometriomas. Fibroblasts grow rapidly, which is a characteristic of ovarian endometrioma. The typical endometrioma is characterized by a unilocular cyst with uniform low-level echogenicity (ground-glass echogenicity) [10, 11]. Endometriomas' look can be indistinguishable from that of HOCs at the start of their creation. Endometriomas accumulate more hemorrhagic debris over time, which is responsible for their classic look (of a unilocular cyst with fluid content expressing ground glass echogenicity) [12]. Clinical settings regularly see hemorrhagic ovarian cysts (HOCs). Except for a small number of circumstances where surgical intervention is indicated, the bulk of them eventually disappear over time [13]. Cyst rupture can occasionally be uncomfortable and require surgery to heal. The chance of other negative outcomes, like hypovolemic shock, can be increased by hemoperitoneum brought on by burst hemorrhagic ovarian cysts [14]. The most common germ cell tumor is mature cystic teratoma, which is made up of one or more of the three primitive germ cell layers. They differ in terms of size and presentation [15]. Ultrasound is useful in the diagnosis of ovarian pathology. Color Doppler can be used to assess the vascularity of a lesion [16]. Because of its real-time nature, USG is a highly cost-effective technique. Because of its portability and low cost, it can be used for point-of-care imaging at the bedside, in emergency rooms, rural clinics, and poor countries [17]. Surgery is recommended for larger, symptomatic cysts. Ovarian cysts or adnexal masses during pregnancy are a frequent occurrence, with reported prevalence ranging from 1% to 5.3 [18]. Ovarian cyst complications can occur, including cyst rupture, bleeding, and twisting. The most common causes of pelvic pain during the first trimester are hemorrhagic ovarian cysts, ovarian torsion, and ectopic pregnancies [19]. It is now simpler to differentiate between benign and malignant ovarian tumors thanks to new imaging techniques. A quick and noninvasive first-choice test for assessing ovarian lesions is Transvaginal Ultrasonography (TVS). The use of color doppler made it possible to identify cases of malignant cysts. Furthermore, the Centers for Disease Control and Prevention survey revealed a 22% prevalence for control [20]. Ovarian cysts often do not require treatment and shrink on their own after one to two months; however, if they distort, bleed, or rupture, they may pose

major issues.

This study aimed to calculate the prevalence of ovarian cysts found on ultrasonography in females visiting tertiary care hospitals who are of reproductive age. The diagnostic method of ultrasound is non-invasive and radiation-safe.

## METHODS

Descriptive cross sectional study was conducted from September to December 2023 on females of reproductive age between 18 to 44 years at diagnostic department of combined Military hospital Lahore. Known probability sampling technique was employed. The study was conducted at CMH Lahore medical college teaching hospital after the approval of ethical review committee having case no of 666/ERC/CMH/LMC. All the patients who fulfill the inclusion and exclusion criteria were enrolled after taking consent. Who are symptomatic or asymptomatic of pelvic pain were included. Women who came for follicular tracking scans and women with 3rd trimester pregnancy were excluded. Detailed history was taken from all the patients including age, sex, duration of pain and associated symptoms like abdominal swelling, pain, bleeding, irregular period. The sample size was 403 and data from 217 women of reproductive age was collected. Age ranging from 18-44 years. Sample size based on sensitivity calculated by this formula [21].  **$Z_{1-\alpha/2} \times SN \times (1-SN) / L^2 \times \text{Prevalence}$** . Where n= required sample size, S N= sensitivity taken as 92%,  $\alpha$ =size of the critical region ( $1-\alpha$  is the confidence level),  $Z_{1-\alpha/2} = 1.96$  at 95% confidence interval, L= taken as 0.05. There were total 217 patients from which data was collected and 137 had normal sonographic characteristic and 80 had ovarian cyst all the examinations were performed using Toshiba Xario, (5-12MHz) curvilinear transducer and transvaginal transducer (5-7MHz). The patients were then being scanned by ultrasound. Full bladder was required for better examination of ovaries. Data were entered and analyzed through SPSS version 26.0. For descriptive analysis, frequencies and percentages were computed for the qualitative data. While mean and standard deviation were calculated for the quantitative data. Every outcome was computed at 95% confidence interval and p value less than or equal to 0.05 will be considered significant.

## RESULTS

The data was collected from total of 217 patients. Out of total 217 Females patients visiting the tertiary care hospital from September to December 2023, the prevalence of ovarian cyst diagnosed on ultrasonography is 36.9. Table 1 illustrates patient age groups ranging from 20 to >40.

**Table 1:** Age Group of Patients(Years)

Variables	Category	Frequency (%)
Age Group of Patients in Years	<20	24 (11.10)
	21-25	42 (19.4)
	26-30	50 (23)
	31-35	49 (22.6)
	36-40	33 (15.2)
	>40	19 (8.8)
	Total	217 (100)

Figure 1 showed prevalence of ovarian cyst which is 36.87%.

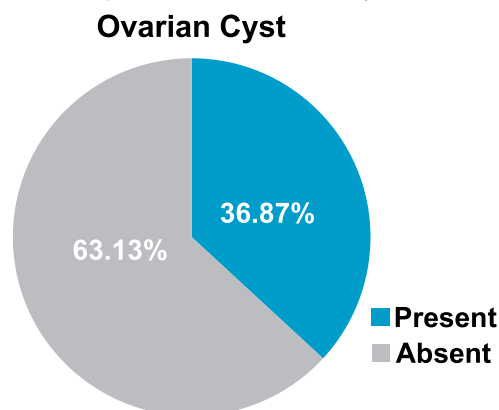
**Figure 1:** Prevalence of Ovarian Cysts

Figure 2 showed distribution of ovarian cyst types. There were total 217 patients in the study from which 137 had normal sonographic characteristics and 80 had ovarian cysts. Females with simple ovarian cysts were 32 (14.7%). Patients with hemorrhagic ovarian cyst were 23 (10.6%). There were 18 (8.3%) patients of PCOS, 3 (1.4%) of dermoid cyst, 2 (0.9%) of patients had mucinous cystadenocarcinoma. Complex cysts were only 2 (0.9%).

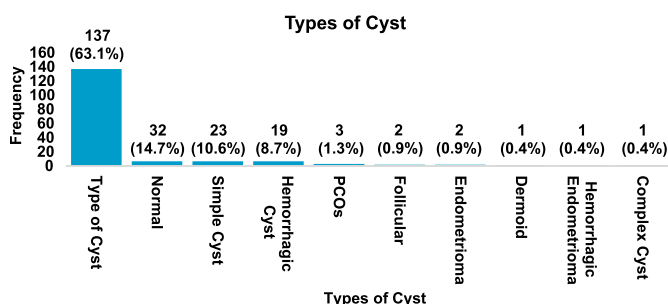
**Figure 2:** Distribution of Ovarian Cysts Types

Table 2 showed clinical symptoms of ovarian cyst in relation to frequency or percentage. There were total 217 patients. The patients of ovarian cysts in which pain was present were 113 (52.1%) and in which pain was absent were 104 (47.9%). Patients who felt difficulty in urination were 10 (4.6%) and who did not feel difficulty in urination were 207 (95.4%). Among the patients 50 (23%) were pregnant and 167 (77%) were non-pregnant. Females who presented with irregular period in the study were 65 (30%) and 152 (70%) had no irregular periods. Patients in which abdominal

swelling was present were 15 (6.9%) and in 202 (93.1%) abdominal swelling was absent.

**Table 2:** Clinical Symptoms of Ovarian Cyst

Clinical Symptoms		
Variables	Options	Frequency (%)
Pain	Absent	104 (47.9)
	Present	113 (52.1)
Difficulty urinating	No	207 (95.4)
	Yes	10 (4.6)
Bleeding	No	190 (87.6)
	Yes	27 (12.4)
Pregnancy	No	167 (77)
	Yes	50 (23)
Irregular period	No	152 (70)
	Yes	65 (30)
Abdominal swelling	No	202 (93.1)
	Yes	15 (6.9)
Total		217 (100)

Table 3 showed ovarian volume of right or left ovaries and size of ovarian cyst. There were 171 patients with normal ovarian volume of both ovaries. 6-12ml which was the most common ovarian volume found in both ovaries. Only 2 patients (1%) who had right or left ovarian volume of 19-26ml and only 4 (1.8%) patients had ovarian volume of 33-40ml. The patients in which size of ovarian cyst was 1-3cm were 11 (5.1%). 3-6cm was most common size in females, had frequency of 53 (24.4%). And ovarian cysts with size of 2-5mm had frequency of 14 (6.5%), 5-30cm had frequency of 2 (0.9%).

**Table 3:** Ovarian Volume and Ultrasound Features of Ovarian Cysts

Ovarian Volume	Right Ovarian Volume Frequency (%)	Left Ovarian Volume Frequency (%)	Other Findings Frequency (%)
Normal	171 (78.8)	171 (78.8)	None: 137 (63.1)
6-12 ml	43 (19.8)	43 (19.8)	1-3 cm: 11 (5.1)
19-26 ml	1 (0.5)	1 (0.5)	3-6 cm: 53 (24.4)
33-40 ml	2 (0.9)	2 (0.9)	2-5 mm: 14 (6.5)
Total	217 (100)	217 (100)	5-30 cm: 2 (0.9)

Table 4 displayed the findings of ovarian cyst on ultrasounds. According to this data, out of the 217 patients who were included in the study, 137 (63.1%) were normal and 80 (36.7%) had ovarian cysts. Ovarian cysts were present in 35 patients (16.6%) in the right ovary and 40 patients (18.4%) in the left. Bilateral ovarian cysts were present in just 5 female cases.

**Table 4:** Ultrasound Findings of Ovarian Cysts

Findings	Category	Frequency (%)
Ovarian Cyst	Absent	137 (63.1)
	Present	80 (36.9)
Ovary Involved	None	137 (63.1)
	Right	35 (16.6)
	Left	40 (18.4)
	Bilateral	5 (2.3)
Total		217 (100)

## DISCUSSION

Gurung *et al.*, Conducted a descriptive study at Kathmandu Medical College Teaching Hospital for two years from 1 January 2011 to 31 December 2012 [22]. The purpose was the histopathological study of ovarian cystic lesions in Nepal. The goal of the study was to identify the morphologic range of ovarian cystic lesions. The Pathology Department received and processed a total of 135 cases of ovarian cysts. Slides stained with hematoxylin and eosin were analyzed. 119 instances (88.15%) of the 135 ovarian cystic lesions were unilateral, while 16 cases (11.85%) were bilateral. Mature cystic teratoma incidence was highest (30%) among ovarian cystic tumors. Mature cystic teratomas were the benign tumors that were most frequently seen. But in this study only 5 (2.3%) ovarian cysts were bilateral and 75 (35%) were unilateral. And in this study simple cysts (14.7%) were more frequent. And had the highest frequency [22]. Ismail conducted a study in 2005 investigated the lateralization of ovarian cystic teratomas, with a specific focus on their higher incidence on the right side, as observed through sonographic imaging [23]. It emphasized the importance of ultrasound in detecting these cysts and discusses potential embryological or anatomical reasons for the right-sided predominance. The aim of the study was to determine the incidence of right-sided ovarian cystic teratoma. The primary data were obtained over two decades and include both retrospective and prospective review. The researcher looked at 270 cases of ovarian cystic teratoma. Ovarian dermoids were identified on the right ovary more frequently than the left ovary in this series. The results show that 195 dermoids (72.22%) were detected on the right ovary, 47 dermoid (17.41%) were found on the left side, and 28 dermoids (10.37%) were found bilaterally. According to the findings, unilateral dermoids are more common on the right side. But in this study only 35 patients (16.6%) had cysts in the right ovary and 40 patients (18.4%) in the left. Bilateral ovarian cysts were present in just 5 (2.3%) female cases [23]. Sohu *et al.*, conducted a study in 2022 evaluated the accuracy of ultrasound in differentiating between benign and malignant ovarian cysts. It correlated clinical findings with imaging data, highlighted the diagnostic value of sonography in ovarian pathology and its role in guiding treatment strategies [24]. This was an observational research, the study was carried out in the Department of Radiology, Ghulam Muhammad Mahar Medical College, Sukkur. The study's goal was to look into the clinical link of ovarian cysts, whether malignant or benign, with ultrasound reports. Ninety-five individuals with an unintentional diagnosis of ovarian mass and symptoms of stomach pain, palpable mass, and menstrual cycle irregularities were included as participants. The average age was 42 years, with 62.3% of the women in reproductive

age and the rest in menopause. 70% had abdominal pain, whereas 2% were asymptomatic. But in this study patients with symptoms of abdominal pain, difficulty urinating, bleeding, pregnancy, irregular period was included. Mean age was 30 years; this study includes women of reproductive age ranging from 18 to 44 years. In this study 52.1% women has abdominal pain [24]. Study limitations: It is important to recognize the limitations of interest. First of all, sample size was 403 people. Due to time constraints, only 217 patient's data were collected. Second Data should be conducted from multiple setups.

## CONCLUSIONS

Ultrasound is an effective, non-invasive and radiation safe modality for the diagnosis and detection of prevalence of ovarian cysts in females of reproductive age. The most common symptom in females was abdominal pain and irregular periods. Ovarian cysts were present in one-third of the target population. The frequency of benign cysts was higher than malignant cysts. A pelvis ultrasound combined with a doppler scan is the modality of choice to diagnose ovarian cysts.

## Authors Contribution

Conceptualization: TE

Methodology: TE

Formal analysis: AR

Writing, review and editing: TE, FB, YK, FS, RA, ZA

All authors have read and agreed to the published version of the manuscript.

## Conflicts of Interest

All the authors declare no conflict of interest.

## Source of Funding

The author received no financial support for the research, authorship and/or publication of this article.

## REFERENCES

- [1] Seidizadeh O, Aliabad GM, Mirzaei I, Yaghoubi S, Abtin S, Valikhani A *et al.* Prevalence of hemorrhagic ovarian cysts in patients with rare inherited bleeding disorders. *Transfusion and Apheresis Science*. 2023 Jun; 62(3): 103636. doi: 10.1016/j.transci.2022.103636.
- [2] Levine D, Patel MD, Suh-Burgmann EJ, Andreotti RF, Benacerraf BR, Benson CB *et al.* Simple adnexal cysts: SRU consensus conference update on follow-up and reporting. *Radiology*. 2019 Nov; 293(2): 359-71. doi: 10.1148/radiol.2019191354.
- [3] Ghosh B and Rufford B. A practical approach to managing post-menopausal women with ovarian cysts. *Obstetrics, Gynaecology & Reproductive Medicine*. 2023 Jun; 33(6): 153-9. doi: 10.1016/j.ogrm.



- 2023.03.001.
- [4] Hoo WL, Yazbek J, Holland T, Mavrellos D, Tong EN, Jurkovic D. Expectant management of ultrasonically diagnosed ovarian dermoid cysts: is it possible to predict outcome?. *Ultrasound in Obstetrics and Gynecology*. 2010 Aug; 36(2): 235-40. doi: 10.1002/uog.7610.
  - [5] Das R and Rajbhandari S. An ovarian dermoid cyst in pregnancy: a rare cause of Intrauterine growth restriction. *Med Phoenix*. 2020 Sep; 5(1): 75-8. doi: 10.3126/medphoenix.v5i1.31422.
  - [6] Kaur N and Ma K. Benign ovarian cysts in premenopausal women. *Obstetrics, Gynaecology & Reproductive Medicine*. 2024 Oct. doi: 10.1016/j.ogrm.2024.10.003.
  - [7] Kobenge FM, Elong FA, Mpono EP, Egbe TO. Management of a Huge Ovarian Cyst in Pregnancy at the Douala General Hospital, Cameroon: A Case Report and Review of the Literature. *Advances in Reproductive Sciences*. 2024 Jun; 12(3): 165-78. doi: 10.4236/arsci.2024.123014.
  - [8] Firdous A, Saqib HA, Zia Ul Islam SN, Ali H, Tahir R, Khan M. Role of doppler ultrasound in detection of malignant lesions in patients presenting with ovarian masses taking histopathology as gold standard. *Pakistan Journal of Medical and Health Sciences*. 2021Feb; 15(3): 654-5.
  - [9] Senarath S, Ades A, Nanayakkara P. Ovarian cysts in pregnancy: a narrative review. *Journal of Obstetrics and Gynaecology*. 2021Mar; 41(2): 169-75.
  - [10] Tehrani HG, Tavakoli R, Hashemi M, Haghighat S. Ethanol sclerotherapy versus laparoscopic surgery in management of ovarian endometrioma; a randomized clinical trial. *Archives of Academic Emergency Medicine*. 2022 Jul; 10(1): e55. doi: 10.22037/aaem.v10i1.1636.
  - [11] Exacoustos C. Sonography for pelvic endometriosis. *Gynäkologische Endokrinologie*. 2023 Sep; 21(3): 165-75. doi: 10.1016/j.jmig.2019.08.027.
  - [12] Ștefan RA, Ștefan PA, Miha CM, Csutak C, Melincovici CS, Crivii CB et al. Ultrasonography in the differentiation of endometriomas from hemorrhagic ovarian cysts: the role of texture analysis. *Journal of Personalized Medicine*. 2021 Jun; 11(7): 611. doi: 10.3390/jpm11070611.
  - [13] Abbas AM, Amin MT, Tolba SM, Ali MK. Hemorrhagic ovarian cysts: Clinical and sonographic correlation with the management options. *Middle East Fertility Society Journal*. 2016 Mar; 21(1): 41-5. doi: 10.1016/j.mefs.2015.08.001.
  - [14] Mantecon O, George A, DeGeorge C, McCauley E, Mangal R, Stead TS et al. A case of hemorrhagic ovarian cyst rupture necessitating surgical intervention. *Cureus*. 2022 Sep; 14(9): e29350. doi: 10.7759/cureus.29350.
  - [15] Farghaly OI. Current diagnosis and management of ovarian cysts. *Clinical and Experimental Obstetrics & Gynecology*. 2014; 41(6): 609-12. doi:10.12891/ceog.20322014.
  - [16] Mais V, Guerriero S, Ajossa S, Angiolucci M, Paoletti AM, Melis GB. The efficiency of transvaginal ultrasonography in the diagnosis of endometrioma. *Fertility and Sterility*. 1993 Nov; 60(5): 776-80. doi: 10.1016/s0015-0282(16)56275-x,
  - [17] Van Sloun RJ, Cohen R, Eldar YC. Deep learning in ultrasound imaging. *Proceedings of the IEEE*. 2019 Aug; 108(1): 11-29. doi: 10.48550/arXiv.1907.02994.
  - [18] Jamdade K and Gajjar K. Management of ovarian cysts and cancer in pregnancy. *Obstetrics, Gynaecology & Reproductive Medicine*. 2025.
  - [19] Samanta R, Anand R, Solanki R, Yadav R. Ultrasonographic evaluation of pelvic pain in first trimester of pregnancy: a prospective study. *International Journal of Reproduction, Contraception, Obstetrics and Gynecology*. 2023 Aug; 12(8): 2417-22. doi: 10.54361/ajmas.2472021.
  - [20] Christensen JT, Boldsen JL, Westergaard JG. Functional ovarian cysts in premenopausal and gynecologically healthy women. *Contraception*. 2002 Sep; 66(3): 153-7. doi: 10.1016/s0010-7824(02)00353-0.
  - [21] Aguer EM, Wangalwa R, Jeninah A, Augustino SM. Microbiological Safety and Quality of Raw Milk at Pastoral Community Cattle Campsites in Rejaf East Payam, South Sudan. *Journal of Food and Nutrition Sciences*. 2025 Feb; 13(1): 28-47. doi: 10.11648/j.jfns.20251301.14.
  - [22] Gurung P, Hirachand S, Pradhanang S. Histopathological study of ovarian cystic lesions in tertiary care hospital of Kathmandu, Nepal. *Journal of Institute of Medicine Nepal*. 2013; 35(3): 44-7. doi: 10.59779/jiomnepal.658.
  - [23] Ismail SR. An evaluation of the incidence of right-sided ovarian cystic teratoma visualized on sonograms. *Journal of Diagnostic Medical Sonography*. 2005 Jul; 21(4): 336-42.
  - [24] Sohu DM, Inayatullah MR, Phul AH, Memon IK, Hafeez R. Clinical Correlation of Ovarian Cyst Malignant or Benign with Ultrasound Reports. *Pakistan Journal of Medical & Health Sciences*. 2022 Jul; 16(06): 328. doi: 10.53350/pjmhs22166328.