

Original article**Iron deficiency and risk of oral squamous cell carcinoma**Imrana Tanvir^{1*}, RizwanUllah Khan², Amber Hassan³ and SamiUllah Mumtaz⁴¹ Pathology Department, King Abdul Aziz University, Rabigh, Saudi Arabia² Pathology Department, Prince Faisal Cancer Center, King Fahad Specialist Hospital, Buraidah, Saudi Arabia³ Research Unit, Faculty of Allied Health Sciences, The University of Lahore, Lahore, Pakistan⁴ North Medical Ward, King Edward Medical University/ Mayo hospital, Lahore, Pakistan

* imrana_tanvir@yahoo.com

Abstract:

Oral squamous cell carcinoma (OSCC) is a subset of head and neck squamous cell carcinoma caused by excessive substance abuse like alcohol, tobacco etc. **Objectives:** Aim of the present study was to evaluate the iron expression in different grades of OSCC and potential of iron staining as a prognostic marker and its importance as an essential nutrient in diet. **Methods and Patients:** It was a cross sectional study. A total of 40 oral biopsies were evaluated and the mean age of patients was 53.5 years with age range 23-80 years. 14 cases were well differentiated, 14 moderately differentiated and there were 12 poorly differentiated case. Iron staining was performed for all these cases. **Results:** Iron positivity was observed in 11(27.5%) of OSCC patients with maximum iron positivity in well differentiated group (64.28%) of age range 20-40 years (70%). More patients had tongue as site of cancer. There was no genderwise difference in iron expression. Iron deficiency was associated with poor prognosis indicating iron as an important nutrient which can prevent OSCC if adequately present in our routine diet. **Conclusions:** Prevalence of iron positivity in young patients and initial stage of OSCC, indicates the protective effect of iron against oral squamous cell carcinoma.

Keywords:

oral cancer, Iron expression, prognostic marker

Introduction:

Head and neck squamous cell carcinoma, a kind of epithelial cancer, is the sixth most common and constitutes for 12 % of all malignancies worldwide [1,2]. It belongs to the biologically similar cancers that includes oral cavity, lip, nasal cavity, pharynx, larynx and paranasal sinuses. Every year, HNSCC accounts for 350,000 cancer deaths and 650,000 new cases approximately and 1000 patients are registered in Scotland with HNSCC yearly [3,4]. Oral squamous cell carcinoma(OSCC) is included in head and neck squamous cell carcinomas and contributes to approximately 90% of all the cancers of HNSCC [5,6]. Amongst young people the increasing incidence of HNSCC have been found. The incidence of disease increases with the increase of age, 85% of the diagnosed cases in UK are

those patients who belongs to the age group of above 50 with more prevalence in males [7,8].

Both genetic and environmental factors such as Pan, beetle nuts, gums, alcohol and tobacco abuse, chemicals, ultraviolet rays and human papilloma virus etc may contribute to the pathogenesis of OSCC [9-11]. Poor oral hygiene is also one of the main etiological factor.

OSCC is becoming a big problem all over the world and its etiological factors are different in different areas of the world. Previously, few studies have been reported regarding the expression of iron in different cancers and in oral squamous cell carcinoma. But there is insufficient information available. The present study aimed at evaluating the association of iron expression with the prognosis of OSCC.

Methods and Patients:

40 cases of confirmed breast carcinoma along with clinical and medical history such as genetic history, tumor location, clinical manifestation, measurements, invasiveness, stage of disease etc were taken from Fatima Memorial College of Medicine and Dentistry, Lahore. There were 11 females and 29 males. In these cases, there were 14 cases of stage I, 14 cases of stage II, III and 12 cases of stage IV. Age of the patients ranged from 20-80 years. Haematoxyline-Eosin staining was performed for all the cases.

Iron Staining:

Slides are first deparaffinized, hydrated in distilled water. Sections are immersed in equivocal amounts of potassium ferrocyanide and hydrochloric acid. 3 washings in distilled water is done and then counterstained with eosin for 5 minutes. If there is any ferric ion present in the tissue sample, it reacts with the ferrocyanide, resulting in a bright blue pigment termed as Prussian blue or ferric ferrocyanide. Dehydration is done in 90% and then 100% alcohol and then pass through 2 changes of xylene before mounting and coverslipping.

Scoring for Stains:

Expression of iron was studied by cell counting in tumor tissue at low and high magnification (Figure 1). Total number of cells in a randomly selected field as well as the iron positive cells were counted and mean percentages were calculated to evaluate the expression of iron. 0-10% positive cells were labelled as negative, 10-30% as weakly stained, 30-60% as moderate staining and 60-100% as strong stained [12]

Results:

In the present study, the mean age of patients with oral squamous cell carcinoma was 53.5 years. More iron positive patients were observed at the age group of 20-40 years (10/40, 25%) and in well differentiated grade (14/40, 35%). Out of 10 positive cases in the age range of 20-40 years, 70% (7/10) were positive for iron (Table 1). Among the 14 well differentiated cases, 64.28% (9/14) were positive for iron (Table 1). According to genderwise distribution, 8 males out of

29(27.58%) and 3 females out of 11 (27.27%) showed the positive results for iron expression. Out of many sites of head and neck region, the maximum number (25%) of biopsies were from the tongue region (Table 1).

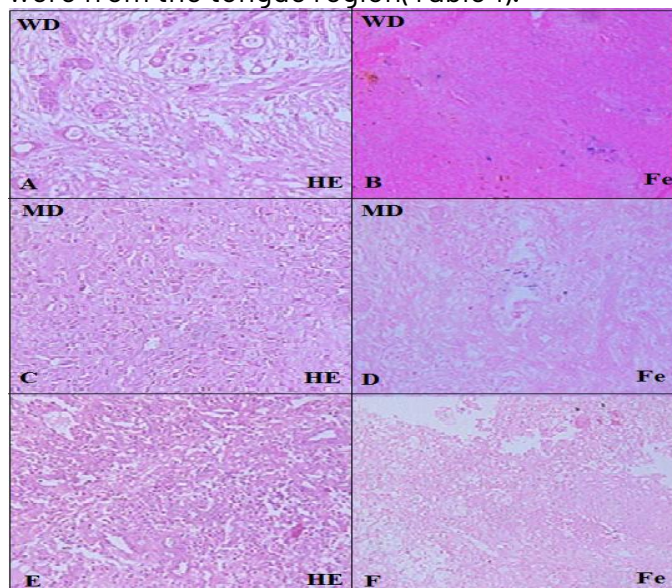


Figure 1: Oral squamous cell carcinoma tissue (25X)- A: H/E stain in WD-OSCC, B: iron staining in WD-OSCC; C: H/E stain in MD-OSCC, D: iron staining in MD-OSCC; E- H/E stain in PD-OSCC, F- iron staining in PD-OSCC (WD-well differentiated, MD-moderately differentiated, PD- poorly differentiated, OSCC- Oral squamous cell carcinoma)

parameters	Fe+(11)	Fe-(29)	Fe+(%)
Age(years)			
20-40	7	3	70
41-60	2	13	13.33
>60	2	13	13.33
Gender			
Male	8	21	27.58
Female	3	8	27.27
Grade			
I (well diff)	9	5	64.28

II (mod)	2	12	14.28
III (poor)	0	12	0
Tumor size(cm)			
<2	2	12	14.28
2-5	5	8	38.46
>5	4	1	80
Tumor site (%)			
Tongue	10	25	
Cheek	7	17.5	
Floor of mouth	6	15	
Vocal cord	4	10	
Buccal area	3	7.5	
Larynx	3	7.5	
Posterior cricoids region	2	5	
Piriform Fossa	1	2.5	
Supra Glottis region	1	2.5	
Marjolin	1	2.5	
Scalp	1	2.5	
Maxillary Sinus	1	2.5	

Table 1: Clinicopathological features of studied patients

Discussion:

Deficiency of iron has known adverse effects on the oral region and also associated with OSCC [13]. Role of diet and nutrition with carcinogenesis is not among the well-studied aspects. Iron is an essential nutritional element and its deficiency is prevalent in poor and developing nations globally. There is possibility that low iron intake might cause oral cancer [14]. Iron deficiency has also been reported to be

associated with other cancers such as lung, colorectal carcinoma [15], breast carcinoma [16] and liver conditions [17]. In current study, an increased iron expression has been observed in early cancerous stage. Stage II and II had moderate iron expression and stage IV had no or minimal expression.

The introduction of iron supplementation in Swedish foods resulted in lower incidence of OSCC [18]. The underlying mechanism may involve the induction of oxidative stress via synthesis of free radicals and reactive oxygen species which can cause cellular damage. This surge in oxidative stress may cause iron deficiency anemia and also associated with OSCC. Dietary supplementation of nutrients and antioxidants may reduce the risk of OSCC [19,20]. Deficiencies of anti-oxidant vitamins and nutrients have been postulated as co factors in the process of carcinogenesis. More specifically, OSCC have been related to low intake of fruits and vegetable that contains iron. Additionally, active ingredients in fruits and vegetables that may act as suppressor agents to control cell growth like indoles, flavonoids etc. green leafy vegetables are good source of iron which have been associated with a reduced risk of iron. The development of tumor of oral and other HNSCCs from dysplasia to metastasis undergoes a series of pathologic phenotypic changes considered to be the significant symptoms of cancer, and these have been accompanied by a number of genetic, epigenetic, and molecular alterations. Several signal transduction pathways have been reported to be changed in oral cancer, causing to dramatic changes in the survival of cell, proliferation of cell, morphology of cell, angiogenesis, longevity, and other properties, characterizing cancer cells [19,20].

People should use those foods that contains proper amount of iron as a preventive measure for oral squamous cell carcinoma. The foods rich in iron are wheat bran, wheat beans, lentils, red (kidney, liver, heart) meat, parsley, oat raw bran, almonds, walnuts, barley, spinach, all leafy green vegetables, eggs, lamb meat, asparagus, black &

red beans and goat cheese. Basically, meats are excellent sources of iron. They contain heme iron, which is very easily absorbed by the body. People can also mainly get iron by eating grains and legumes, but they should prepare them properly, as they contain anti-nutrients that could prevent the absorption of the iron they contain. If people don't like these foods then they can take iron supplements too. These are dietary supplements that are prescribed by a doctor and can be delivered orally, intravenously and intramuscularly. As our study indicated that the more oral cancer ratio comes in males, they should put more emphasis on the intake of iron along with other measures such as oral hygiene. Severe iron deficiency is the main arrival to immune compromise, which may enhance the proliferation of cancer.

Conclusions:

We suggest giving iron supplements to the OSCC patients because the quantity of iron is decreased as the disease progresses. Our study suggests that deficiency of iron in the body may lead to oral squamous cell carcinoma.

References:

1. Allen, C. T., Law, J. H., Dunn, G. P., & Uppaluri, R. (2013). Emerging insights into head and neck cancer metastasis. [Review]. *Head Neck*, **35**(11), 1669-1678. doi: 10.1002/hed.23202
2. Bose, K. S., Gokhale, P. V., Dwivedi, S., & Singh, M. (2013). Quantitative evaluation and correlation of serum glycoconjugates: Protein bound hexoses, sialic acid and fucose in leukoplakia, oral sub mucous fibrosis and oral cancer. *J Nat Sci Biol Med*, **4**(1), 122-125. doi: 10.4103/0976-9668.107275
3. Diallo, A., Deschasaux, M., Partula, V., Latino-Martel, P., Srouf, B., Hercberg, S., . . . Touvier, M. (2016). Dietary iron intake and breast cancer risk: modulation by an antioxidant supplementation. [Clinical Trial]. *Oncotarget*, **7**(48), 79008-79016. doi: 10.18632/oncotarget.12592
4. Dreyer, J. H., Hauck, F., Oliveira-Silva, M., Barros, M. H., & Niedobitek, G. (2013). Detection of HPV infection in head and neck squamous cell carcinoma: a practical proposal. [Research Support, Non-U.S. Gov't]. *Virchows Arch*, **462**(4), 381-389. doi: 10.1007/s00428-013-1393-5
5. Hallberg, L., Bengtsson, C., Garby, L., Lennartsson, J., Rossander, L., & Tibblin, E. (1979). An analysis of factors leading to a reduction in iron deficiency in Swedish women. *Bull World Health Organ*, **57**(6), 947-954.
6. Li, S. Y., Hu, J. A., & Wang, H. M. (2013). Expression of Yes-associated protein 1 gene and protein in oral squamous cell carcinoma. *Chin Med J (Engl)*, **126**(4), 655-658.
7. Ludwig, H., Evstatiev, R., Kornek, G., Apro, M., Bauernhofer, T., Buxhofer-Ausch, V., . . . Link, H. (2015a). Erratum to: Iron metabolism and iron supplementation in cancer patients. [Published Erratum]. *Wien Klin Wochenschr*, **127**(23-24), 920-921. doi: 10.1007/s00508-015-0893-5
8. Ludwig, H., Evstatiev, R., Kornek, G., Apro, M., Bauernhofer, T., Buxhofer-Ausch, V., . . . Link, H. (2015b). Iron metabolism and iron supplementation in cancer patients. [Review]. *Wien Klin Wochenschr*, **127**(23-24), 907-919. doi: 10.1007/s00508-015-0842-3
9. Macfarlane, G. J., Boyle, P., & Scully, C. (1992). Oral cancer in Scotland: changing incidence and mortality. *BMJ*, **305**(6862), 1121-1123.
10. Mafi, N., Kadivar, M., Hosseini, N., Ahmadi, S., & Zare-Mirzaie, A. (2012). Head and neck squamous cell carcinoma in Iranian patients and risk factors in young adults: a fifteen-year study. *Asian Pac J Cancer Prev*, **13**(7), 3373-3378.
11. Mehboob, R., Tanvir, I., Warraich, R. A., Perveen, S., Yasmeen, S., & Ahmad, F. J. (2015). Role of neurotransmitter Substance P in progression of oral squamous cell carcinoma. [Research Support, Non-U.S. Gov't]. *Pathol Res Pract*, **211**(3), 203-207. doi: 10.1016/j.prp.2014.09.016

12. Munoz, M., Gomez-Ramirez, S., Besser, M., Pavia, J., Gomollon, F., Liunbruno, G. M., . . . Auerbach, M. (2017). Current misconceptions in diagnosis and management of iron deficiency. [Review]. *Blood Transfus*, **15**(5), 422-437. doi: 10.2450/2017.0113-17
13. Musallam, K. M., & Taher, A. T. (2018). Iron deficiency beyond erythropoiesis: should we be concerned? [Review]. *Curr Med Res Opin*, **34**(1), 81-93. doi: 10.1080/03007995.2017.1394833
14. Neville, B. W. (2007). Update on current trends in oral and maxillofacial pathology. [Congresses]. *Head Neck Pathol*, **1**(1), 75-80. doi: 10.1007/s12105-007-0007-4
15. Parkin, D. M., Bray, F., Ferlay, J., & Pisani, P. (2005). Global cancer statistics, 2002. *CA Cancer J Clin*, **55**(2), 74-108.
16. Stein, J., Connor, S., Virgin, G., Ong, D. E., & Pereyra, L. (2016). Anemia and iron deficiency in gastrointestinal and liver conditions. [Review]. *World J Gastroenterol*, **22**(35), 7908-7925. doi: 10.3748/wjg.v22.i35.7908
17. Strojan, P., Corry, J., Eisbruch, A., Vermorken, J. B., Mendenhall, W. M., Lee, A. W., . . . Ferlito, A. (2015). Recurrent and second primary squamous cell carcinoma of the head and neck: when and how to reirradiate. [Review]. *Head Neck*, **37**(1), 134-150. doi: 10.1002/hed.23542
18. Termine, N., Panzarella, V., Falaschini, S., Russo, A., Matranga, D., Lo Muzio, L., & Campisi, G. (2008). HPV in oral squamous cell carcinoma vs head and neck squamous cell carcinoma biopsies: a meta-analysis (1988-2007). [Meta-Analysis Review]. *Ann Oncol*, **19**(10), 1681-1690. doi: 10.1093/annonc/mdn372
20. Wilson, M. J., Dekker, J. W. T., Harlaar, J. J., Jeekel, J., Schipperus, M., & Zwaginga, J. J. (2017). The role of preoperative iron deficiency in colorectal cancer patients: prevalence and treatment. *Int J Colorectal*

Dis, **32**(11), 1617-1624. doi: 10.1007/s00384-017-2898-1