



Original Article

Evaluation of Breast Lesions Using Mammography

Mah Noor¹, Akash John¹, Abid Ali¹, Amna Yousaf¹, Khadija Bakhtawar¹¹Department of Allied Health Sciences, University Institute Of Radiological And Medical Imaging Sciences, The Univeristy of Chenab, Gujrat, Pakistan

ARTICLE INFO

Key Words:

Breast, Lesions, Cancer, Tumors, Mammography

How to Cite:

Mah Noor, ., John, A., Ali, A. ., Yousaf, A. ., & Bakhtawar, K. . (2022). Evaluation of Breast Lesions Using Mammography: Evaluation of Breast Lesions Using Mammography. *Pakistan BioMedical Journal*, 5(6). <https://doi.org/10.54393/pbmj.v5i6.545>
<https://doi.org/10.54393/pbmj.v5i5.451>

*Corresponding Author:

Mahnoor

Department of Allied Health Sciences, University Institute Of Radiological And Medical Imaging Sciences, The Univeristy of Chenab, Gujrat, Pakistan

Received Date: 12th June, 2022Acceptance Date: 26th June, 2022Published Date: 30th June, 2022

ABSTRACT

The second leading cause of death is breast cancer and annual mammograms have been found to incite the early identification of breast cancer. The diagnosis of cancer at initial stage is helpful in lowering the mortality rate. The most prevalent pathologies of breast cancer are swelling, cysts, and adenosis, and benign or malignant tumors. **Objective:** To evaluate Breast Lesions Using Mammography. **Method:** It was a cross-sectional study comprised of a sample size of 47 female patients, calculated via a convenient sampling approach by taking mean of three previous published studies. Women with age of 29 years and above were included in this study. The study was performed in Faisalabad, Pakistan from December 2021 to March 2022. The digital mammographic equipment was used in this study and data was entered and analyzed by SPSS version 20. **Results:** The majority 33(70.2%) patients were included in 30-49 years age group while least were 2(4.3%) in 70 and above. The ill-defined shape tumors were 18 (38.3%) and the the microlobulated shaped tumors were 1(2.1%). The tumors with well-defined margin were 17(36.2%) and tumors with ill-defined margin were 1(2.1%). The tumors without calcification were 31(66%) and the calcified tumors were 16(34%). The tumors with involvement of lymph nodes were 30(63.8) and tumors with single lymph node involved were 1(2.1%) **Conclusion:** A mammogram is necessary for determining the stage of breast cancer. A mammogram can be very useful to determine the location and shape of the lesion for demonstrating a lesion's radiographic features.

INTRODUCTION

Among American women, the second leading cause of death is breast cancer, after lung cancer [1]. Among women of United States, the most frequent type of cancer is breast cancer, excluding skin cancers [2]. One in every eight women is affected with breast cancer at some point in their lives (12%). The most common cause of cancer mortality is breast cancer in women [3]. Breast cancer mortality has been lowering as a result of early discovery, management, and postoperative treatment [5]. For breast cancer screening, mammography is the primary method [6]. It's widely available, well-tolerated, and reasonably priced [7,8]. Women aged 40 to 74 years old have shown an increased mortality risk in randomized controlled studies [9]. Mammography has been proven in several trials to be

especially advantageous for women over the age of 80 years [10,11]. Breast cancer was detected in one out of every seven women in 2007 [12]. Mammography can identify changes in the breast up to two years before symptoms occurrence, mammography is critical in the early identification of breast cancer [13]. The United State Department of Health and Human Services has issued new rules [14]. The Department of Health and Human Services (HHS) and the American College of Radiology (ACR) both suggest screening [15]. Beginning at the age of 40 years, women should have a mammogram every year [16]. Annual mammograms have been found to incite to early identification of breast cancers, when they are treatable and breast-conservation medicines are accessible [17].

The breast is a gland that causes perspiration and its major role is to breastfeed children [18]. Fortunately, with better treatment options, severe mastectomy (surgical excision) is rarely needed nowadays [19]. The breasts of a women keeps a significant volume during pubescence, which can enlarge by one-third during lactation [20]. In breast, mammary gland is a gland that produces milk [21]. The breasts do not start to expand until pubescence, at which point the skin of the breasts extends to accommodate different forms and sizes [22]. Acinar cells, which are grouped in the lobules and connect with the outside through the lactiferous canals, undergo hypertrophy and activation, resulting in the production and secretion of milk [23]. Breast size increases as a result of stimulation by hormone during menstrual cycle, lactation and pregnancy, besides hormone therapy and obesity [24]. Early in fetal development, the breast is formed by an invagination of the ectoderm of the embryo's ventral region [25,26]. Despite this, some women retain remains of these atrophied structures, and their breasts are more or less complete from the axilla to the groin [27]. The inverted nipples, hypertrophy and gynecomastia in males are all possible anomalies [28]. Mastitis, abscesses, fat necrosis, benign mammary dysplasia, cysts, fibroadenoma and carcinoma are the most common diseases [29]. It's vital to receive a diagnosis as soon as feasible because of the frequency of changes [30]. This demands regular medical checks, as well as breast self-examination, and gynecological treatment regularly [31]. The study's goal was to find mammographic criteria to distinguish between breast lesions. This research helps the physician to compare mammographic masses (malignant or benign) with clinical breast complaints such as palpable lumps, localised pain, and suspicious nipple discharge. The correlation in ages, presence of calcification, margin, and appearance of lymph node enlargements were all used to detect malignant tumours.

METHODS

It was a cross-sectional study comprised of a sample size of 47 female patients after informed consent, calculated via a convenient sampling approach by taking mean of three previous published studie [8,11,32]. The research was performed in Faisalabad, Pakistan from December 2021 to March 2022. Women with age below 29 years were not included in this study. The digital mammography was employed in this study. Females with clinical breast complaints and abnormal mammograms were included in this research. Data were entered and analyzed by SPSS version 20.

RESULTS

Table 1 shows that the age is distributed into four groups.

maximum age frequency of 33(70.2%) is seen in 30-49 years and a minimum frequency of 2(4.3%) is seen in 70 & above years. Table 2 shows the maximum frequency of ill define shape 18 (38.3%) and the minimum frequency of microlobulated shape of 1(2.1%). Table 3 shows the maximum frequency of a well-defined margin of 17(36.2%) and show minimum frequency of an ill-defined margin of 1(2.1%). Table 4 shows the maximum frequency of calcification is absent at 31(66%) and shows the minimum frequency of present calcification at 16(34%). Table 5 shows the maximum frequency of absence of lymph node 30(63.8) and show minimum frequency of single lymph node of 1(2.1%)

Age of patient				
Valid	Frequency	Percent	Valid Percent	Cumulative Percent
<29	2	4.3	4.3	4.3
30-49	33	70.2	70.2	74.5
50-69	10	21.3	21.3	95.7
70 & above	2	4.3	4.3	100.0
Total	47	100.0	100.0	

Table 1: frequency distribution of patient's age

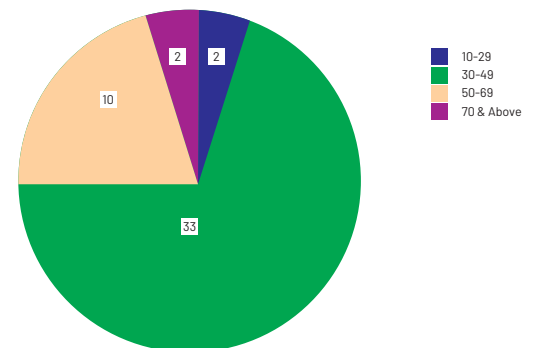


Figure 1: frequency distribution of patient's age

Shape of tumor				
Valid	Frequency	Percent	Valid Percent	Cumulative Percent
round	3	6.4	6.4	6.4
round & oval	2	4.3	4.3	10.6
ill defined	18	38.3	38.3	48.9
microlobulated	1	2.1	2.1	51.1
oval	13	27.7	27.7	78.7
speculated	1	2.1	2.1	80.9
tubal	2	4.3	4.3	85.1
well defined	7	14.9	14.9	100.0
Total	47	100.0	100.0	

Table 2: frequency distribution of tumor's shape

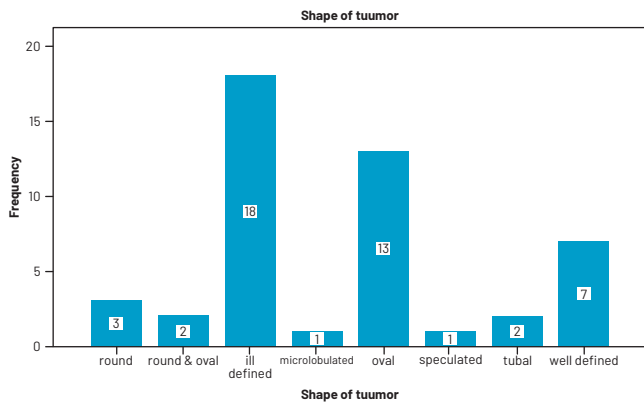


Figure 2: frequency distribution of tumor's shape

Margin of tumor				
Valid	Frequency	Percent	Valid Percent	Cumulative Percent
round	3	6.4	6.4	6.4
ill defined	1	2.1	2.1	8.5
irregular	1	2.1	2.1	10.6
lobulated	6	12.8	12.8	23.4
loculated	2	4.3	4.3	27.7
well-defined	17	36.2	36.2	63.8
obscured	2	4.3	4.3	68.1
oval	2	4.3	4.3	72.3
speculated	13	27.7	27.7	100.0
Total	47	100.0	100.0	

Table 3: frequency distribution of tumor's margin

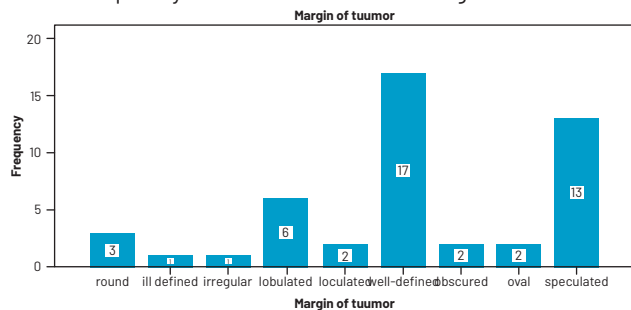


Figure 3: frequency distribution of tumor's margin

Calcification				
Valid	Frequency	Percent	Valid Percent	Cumulative Percent
present	16	34.0	34.0	34.0
absent	31	66.0	66.0	100.0
Total	47	100.0	100.0	

Table 4: frequency distribution of calcification

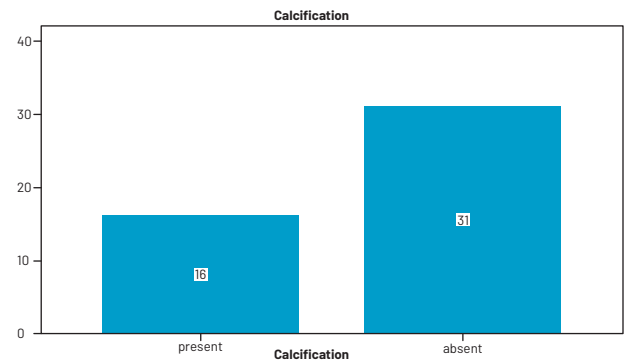


Figure 4: frequency distribution of calcification

Lymph nodes involvement				
Valid	Frequency	Percent	Valid Percent	Cumulative Percent
present	15	31.9	31.9	31.9
absent	30	63.8	63.8	95.7
single	1	2.1	2.1	97.91
multiple	1	2.1	2.1	100.0
Total	47	100.0	100.0	

Table 5: frequency distribution of lymph nodes involvement

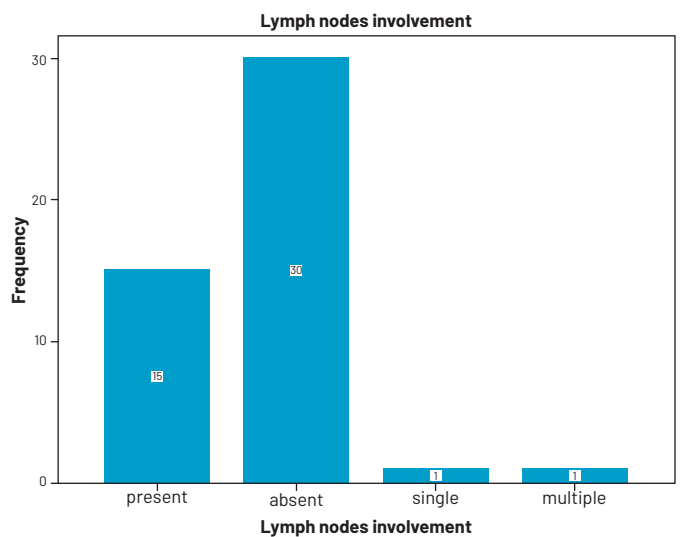


Figure 5: frequency distribution of lymph nodes involvement

DISCUSSION

One in every eight women affected by breast cancer. Breast cancer mortality has been lowering as a result of early discovery, management, and postoperative treatment. For breast cancer screening, mammography is the primary method. In the current study, the age was distributed into four groups. Maximum age frequency of 33(70.2%) is seen in 30-49 years and a minimum frequency of 2(4.3%) is seen in 70 & above years. Another previously published study by Eatizaz Abdelkareem Ahmed Alazhari published in 2017 has similar results that the most affected age group is (40-50) years. In the current study, the maximum frequency of an ill-defined shape was 18 (38.3%), and the minimum frequency of a microlobulated shape of 1(2.1%). Another

previously published study by Ali et.al., published in 2016 has similar results that the mean age is 50-52 years. In the current study the maximum frequency of a well-defined margin of 17(36.2%) and show minimum frequency of an ill-defined margin of 1(2.1%). Another previously published study by Salih et.al., published in 2015 has similar results that found that well defined margins were 16(25%) and speculated angulation were 13(20.3%). In the current study, the maximum frequency of calcification was absent at 31(66%) and showed the minimum frequency of present calcification at 16(34%). Another previously published study by Ali et.al., published in 2016 shows microcalcification 33%. In the current study, patients with absent lymph node were 30(63.8%), and single lymph node 1(2.1%). Another previously published study by Salih et.al., published in 2015 found the appearance lymph with majority of absent in 41(64.1%) and present in 20(31.2%).

CONCLUSION

Mammography is used to investigate breast disease such as lesions. A mammogram is necessary for determining the stage of breast cancer and is useful for demonstrating a lesion's radiographic features. The study found that the lesions were common in 30 to 49 years of age. The most frequent tumors diagnosed using mammography was ill-defined tumors in shape and calcifications were absent in most cases.

REFERENCES

- [1] Sung h, ferlay j, siegel rl, laversanne m, soerjomataram i, jemal a, et al. Global cancer statistics 2020: globocan estimates of incidence and mortality worldwide for 36 cancers in 185 countries. *Ca: a cancer journal for clinicians*. 2021;71(3):209-249.
- [2] Miller kd, fidler-benaoudia m, keegan th, hipp hs, jemal a, siegel rl. Cancer statistics for adolescents and young adults, 2020. *Ca: a cancer journal for clinicians*. 2020;70(6):443-459.
- [3] Wishart gc, azzato em, greenberg dc, rashbass j, kearins o, lawrence g, et al. Predict: a new uk prognostic model that predicts survival following surgery for invasive breast cancer. *Breast cancer research*. 2010;12(1):1-10.
- [4] Olfson m, gerhard t, huang c, crystal s, stroup ts. Premature mortality among adults with schizophrenia in the united states. *Jama psychiatry*. 2015;72(12):1172-1181.
- [5] Leong sp, shen z-z, liu t-j, agarwal g, tajima t, paik n-s, et al. Is breast cancer the same disease in asian and western countries? *World journal of surgery*. 2010;34(10):2308-2324.
- [6] Bleyer a, baines c, miller ab. Impact of screening mammography on breast cancer mortality. *International journal of cancer*. 2016;138(8):2003-12.
- [7] Kelly km, dean j, comulada ws, lee s-j. Breast cancer detection using automated whole breast ultrasound and mammography in radiographically dense breasts. *European radiology*. 2010;20(3):734-742.
- [8] Ali sbma. Study of breast disease using mammography: sudan university of science and technology; 2016.
- [9] Jacobs ij, menon u, ryan a, gentry-maharaja, burnell m, kalsi jk, et al. Ovarian cancer screening and mortality in the uk collaborative trial of ovarian cancer screening (ukctocs): a randomised controlled trial. *The lancet*. 2016;387(10022):945-956.
- [10] Lee ch, dershaw dd, kopans d, evans p, monsees b, monticciolo d, et al. Breast cancer screening with imaging: recommendations from the society of breast imaging and the acr on the use of mammography, breast mri, breast ultrasound, and other technologies for the detection of clinically occult breast cancer. *Journal of the american college of radiology*. 2010;7(1):18-27.
- [11] Salih mha. Characterization of breast tumors using mammography: sudan university of science and technology; 2015.
- [12] Liu l, rissling m, natarajan l, fiorentino l, mills pj, dimsdale je, et al. The longitudinal relationship between fatigue and sleep in breast cancer patients undergoing chemotherapy. *Sleep*. 2012;35(2):237-245.
- [13] Milosevic m, jankovic d, milenkovic a, stojanov d. Early diagnosis and detection of breast cancer. *Technology and health care*. 2018;26(4):729-759.
- [14] Health udo, services h. Us department of agriculture. 2015-2020 dietary guidelines for americans. December 2015. 2019.
- [15] Seung sk, larson da, galvin jm, mehta mp, potters l, schultz cj, et al. American college of radiology (acr) and american society for radiation oncology (astro) practice guideline for the performance of stereotactic radiosurgery (srs). *American journal of clinical oncology*. 2013;36(3):310.
- [16] Arleo ek, hendrick re, helvie ma, sickles ea. Comparison of recommendations for screening mammography using cisnet models. *Cancer*. 2017;123(19):3673-3680.
- [17] Schneble ej, graham lj, shupe mp, flynt fl, banks kp, kirkpatrick ad, et al. Current approaches and challenges in early detection of breast cancer recurrence. *Journal of cancer*. 2014;5(4):281.
- [18] Sabha bh, alzhairani f, almehdar ha, uversky vn,

- redwan em. Disorder in milk proteins: lactadherin multifunctionality and structure. *Current protein and peptide science*. 2018;19(10):983-997.
- [19] Mauermann e, ruppen w, bandschapp o. Different protocols used today to achieve total opioid-free general anesthesia without locoregional blocks. *Best practice & research clinical anaesthesiology*. 2017;31(4):533-545.
- [20] Pawłowski b, żelaźniewicz a. The evolution of perennially enlarged breasts in women: a critical review and a novel hypothesis. *Biological reviews*. 2021;96(6):2794-809.
- [21] Macias h, hinck l. Mammary gland development. *Wiley interdisciplinary reviews: developmental biology*. 2012;1(4):533-557.
- [22] Fuqua js. Treatment and outcomes of precocious puberty: an update. *The journal of clinical endocrinology & metabolism*. 2013;98(6):2198-2207.