

Original Article

Endoscopic Versus Open Radial Artery Harvesting Used in Coronary Artery Bypass Grafting, Our Experience at Queen Alia Heart Institute

Bashar Albkhoor^{1*}, Bahi Hyasat¹, Haitham Altaani¹, Khaled Alnawaiseh¹, Salah Altarbsheh¹, Ziad Alshwabkeh¹, Razi Abu Anzeh¹, Safwan Alfawares¹, Abdallah Alqaisi¹, Mohammad Yanal Alnaser¹ and Said Jaber¹

¹Queen Alia Heart Institute, Amman, Jordan

*albkhoorbashar@gmail.com

Abstract:

Coronary artery stenosis bypass by using radial artery is good techniques which have longer outcomes. In coronary artery bypass grafting (CABG) the radial artery has several advantages. The radial artery has a thick muscular wall which is more susceptible to contraction from the competitive flow. As compared to the open harvesting technique endoscopic harvest of the radial artery has long lasting cosmetic results it also reduces the post-operative complications. The purpose of the study is to compare the two harvesting techniques and compare the short term and long term results related to intra-operative and post-operative outcomes

Methods: This is retrospective study (In Queen Alia Heart Institute, Amman, Jordan) to compare endoscopic radial artery technique versus open technique by reviewing patients files through a period between June 2013 and June 2018. Total 50 patients of CABG surgery was selected they were divided into two groups. Group A includes endoscopic radial harvest (n= 10) and Group B includes open harvest (n=40). Data was collected on predesigned Performa. Data were entered and analyze through IBM SPSS 22.0

Results: There was insignificant dissimilarity between the pre-operative outcomes between groups. The Post-operative outcomes were almost same in both groups except hand numbness (P-value<0.005). The comparison of intraoperative outcomes like harvest time between both groups indicate that the mean harvest time in group A was shorter than group B (39.20 ± 3.73 Vs 51.90 ± 2.09 , P-value=0.000). The operative time in group A was higher than the group B ($306.0 + 11.6$ Vs $278 + 4.25$ p-value=0.00). The hospital stays in both groups were insignificantly different (p = 0.09)

Conclusions: Endoscopic radial artery harvest is best suited technique for CABG surgery as it significantly decreases the harvest time as well as hospital stay. It is also proven that it is safer, less painful and better wound appearance technique with exceptional outcomes based on positive surgical experience.

Key Words: Endoscopic radial artery, coronary artery stenosis, CABG, radial artery harvesting

Introduction:

In young patients coronary artery stenosis bypass by using radial artery is a good technique which have longer outcomes [1, 2]. The radial artery in coronary artery bypass grafting (CABG) has several benefits as a conduit. The patients who were obese, diabetic and have chronic pulmonary disease where the sternal infection rate was increased due to bilateral harvesting of

the internal mammary arteries, as substitute to the right internal mammary artery (RIMA) the radial artery can be used. It produces effective results [3]. The radial artery have a thick muscular wall which is more susceptible to contraction from the competitive flow therefore, it is advised to put the radial artery on critical lesions with the very faint native

antegrade flow [4]. In the internal mammary artery the proximal end of the radial artery can be anastomosed sequentially in to the aorta or as a composite T or Y graft [5].

For the harvesting of radial artery two procedures were used. Traditional technique which is open harvesting and other one is a new technique which is called endoscopic harvesting. In Open harvesting technique requires large longitudinal forearm incision in the radial artery which requires long harvest time and causes increased wound-related problems [6]. Firstly in 1990 the endoscopic vessel harvesting technique was introduced, which used for saphenous vein harvesting. But later on in 2001, this technique was imply for the radial artery harvesting. This technique got popularity in the year 2005, in harvesting the saphenous and radial artery it was used over a large scale and now, in USA hospitals about 80% of CABG patients have endoscopically harvested both radial artery and saphenous vein [7].

Methods:

This is retrospective study (In Queen Alia Heart Institute, Amman, Jordan) to compare endoscopic radial artery technique versus open technique by reviewing patients files through a period between June 2013 and June 2018. Total 50 patients of CABG surgery was selected and distributed into two groups. Group A includes endoscopic radial harvest (n= 10) and Group B includes open harvest (n=40). According to the preferences of surgeons and endoscopic availability patients were assigned into two groups. Data was collected on predesigned Performa. It was divided into two parts preoperative outcome (Age, gender, comorbidities etc.), Intraoperative outcomes (operative time, harvest time) and post-operative outcomes (Complications). Ethical approval of the study was approved by ethical committee of Royal Jordan Medical Services Amman, Jordan. The patients age group of 20-60 and who have CABG surgery of more than 2 vessels diseased were included in the study. Patients who have emergent CABG surgery and

have radial dependent hand circulation or radial anastomosis.

Surgical procedures:

Endoscopic harvesting

The (Vasoview Endoscopic Vessel Harvesting System MAQUET cardiovascular santa clara, CA) was used for endoscopic harvesting. at the beginning we evaluate the pulsation in non-dominant hand by using Allens test as well as around 2 cm incision had been done in the flexor part of the hand immediately over the radial artery near to the distal part of forearm then we had used electrocautery by using camera for guiding to direct exposure of the artery with using CO2 inflation under pressure of 10 mmHg. Dissection of fascia had been done to expose the radial artery and Vena Comitans with application of tourniquet (inflation pressure around 100 mmHg) to prevent ante-grade flow of artery. After anterior and posterior dissection of radial artery through using Conical Tip Endoscope to avoid the contact with the artery and avoid arterial spasm, finally we divide then ligate the pedicles then withdraw them. we preparing the artery by soaking and flushing it with (papaverine and heparinized blood) before clipping it's branches.

Open harvesting

Evaluation of non-dominant hand by Allens test before the procedure. The exposure of the artery had been done through skin incision at the flexor part of forearm just above the radial artery after that, we start mobilization of radial artery with Cotton Tape around the distal radial artery to avoid manipulation and direct contact of artery. then the process of dissection of radial artery from either side of pedicles is proceeded by using electro cautery then dividing the artery at antecubital fossa (proximally then distally) Finally we prepare the artery by flush it with heparinized blood and Papaverine to keep it open and avoid arterial spasm. Last step the Hemostasis had been secured in the field then closed the hand.

Statistical analysis

Data were entered and analyze through IBM SPSS 22.0. Quantitative variables were presented by mean \pm Ad and qualitative with the help of Frequency and percentages. Chi square and fisher exact test was applied to check the association between group and pre-operative and post -operative outcomes. Independent sample t test was applied to test the difference between hospital stay, harvest time and operative time in both groups. Significant *p-value* was considered as < 0.05 .

Results:

The average age in group A and B were 49.30 ± 3.9 and 49.75 ± 5.790 respectively. Group B have

30 (75%) males as compared with group A 7 (70.0%). There was insignificant difference between the preoperative outcomes between both groups.(Table 1). The post-operative outcomes were almost same in both groups except hand numbness (P -value <0.005) (Table 2). The mean harvest time in group A was shorter than group B (39.20 ± 3.73 Vs 51.90 ± 2.09 , P -value = 0.000)(Figure 1)(Table no 2). The operative time in group A was higher than the group B ($306.0 + 11.6$ Vs $278 + 4.25$ p -value= 0.000) (Figure no 1)(Table no 2) There is a insignificant difference between hospital stays in both groups ($p = 0.09$)(Table 2).

Variable	Group A	Group B	P-value
Age(Years)	49.30 ± 3.9	49.75 ± 5.790	0.818
Gender(Male)	7(70.0%)	34(85.0%)	0.249
Diabetes Mellitus	7(70.0%)	33(82.5%)	0.397
Previous History of Stroke	1(10.0%)	5(12.5%)	0.556
Renal failure	2(20.0%)	5(12.5%)	0.541
Hypertension	8(80.0%)	35(87.5%)	0.616

Table No.1: Preoperative outcomes

Variable	Group A	Group B	P-value
Chest Re-Exploration	3(30.0%)	2(5.0%)	0.048
Wound infection	2(20.0%)	3(7.5%)	0.239
Hand Numbness	4(40.0%)	2(5.0%)	0.002
Radial Injury	1(10.0%)	0(0.0%)	0.037
Hematoma	1(10.0%)	12(12.5%)	0.54
Post-Operative Outcome			
Harvest time (minz)	39.20 ± 3.73	51.90	0.000
Operative time (minz)	306.0 ± 11.64	278.28 ± 4.255	0.000
Hospital Stay (Days)	7.20 ± 1.13	8.30 ± 1.137	0.09

Table No.2: Post-operative and Intra-operative outcomes

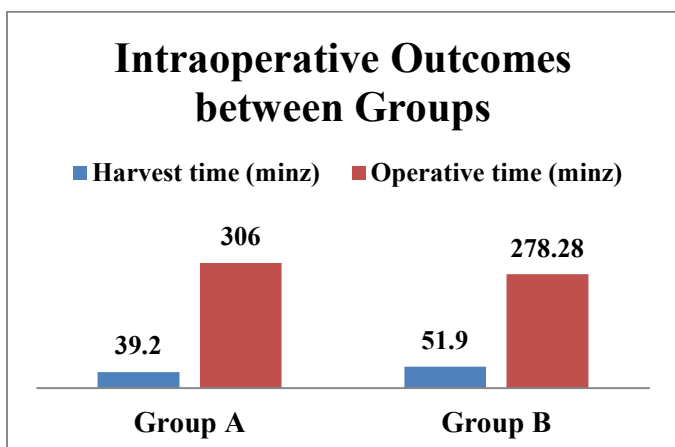


Figure 1: Intraoperative Outcomes between Groups

Discussion:

In CABG patients after internal thoracic arteries the radial artery is being used as a 2nd or 3rd highest harvesting technique [8]. The radial artery has an extensive patency rate than the saphenous vein [9]. The reason behind the successful and extensive term benefits of Radial artery harvest is that its distal end is subcutaneous, its diameter is large and its pulse can be sensed without any problem, which was useful for both distal and proximal anastomosis [10]. The length of radial artery was good which gives an easy option for harvesting [11], Leg wound has higher rate of infection as compared to forearm and moreover it has neurological complications [12]. The significance of radial artery harvesting was increased by the presence of calcium channel blockers which helps and protects the graft from arterial contraction [13]. The shortcoming of Open radial artery harvesting is that it leaves a lengthy scar on forearm which leads to wound infection. It also causes complications after surgery. Several studies reported a new technique called endoscopic harvesting which is adopted by many surgeons. It has better cosmetic results and reduces wound infection and forearm complications [14]. It is very important that the endoscopic harvesting requires prolonged practice as compared to the open harvesting technique. It should be conducted by trained surgeons [15]. Our experience during this research has ups and downs at starting. The rate

of complications and during endoscopic technique but as time gradually This is retrospective study (In Queen Alia Heart Institute , Amman ,Jordan) to compare endoscopic radial artery technique versus open technique by reviewing patients flies through a period between June 2013 and June 2018. The purpose of the study is to compare the two harvesting techniques and compare the short term and long term results related to intra-operative and post-operative outcomes.

In current research we compared intraoperative and post-operative outcomes like hematoma, chest re-exploration, wound infection, hand numbness, harvest time, operative time and hospital stay of CABG patients. The post-operative outcomes were almost same in both groups except hand numbness. When we compared the complication in both group it was observed that hematoma and infection was higher in open harvest as compared to endoscopic group. These findings were in accordance to another study in which they reported that in comparison to endoscopic harvest technique, open technique has higher complications. [16]. Several other reported study also showed that there is a significant decline in the complications rate which is hematoma and infection in endoscopic technique as compared to open harvest technique. [17].

During endoscopic harvesting it was reported that nerve injury and hand numbness is very common, the reason of its occurrence is due to excessive cauterization that occurs in the terminal part of the radial artery near the wrist reflecting less experience of harvesting. [18]. In a randomized controlled trial it was reported that the post-operative outcome, the neurological complications had also occurred [14]. In current study we also reported less neurological complications in the endoscopic harvest technique. These findings were also similar to a prospective study in which they reported that the neurological complication reduces from 10 to 0% [19, 20]. In our study we

observed a complications that occurred mostly was chest re-exploration in endoscopic radial harvest (group A = 3/10 and Group B = 2/40). The reason behind these complications is inadequate experience of the endoscopic technique.

The post-operative outcomes like hospital stay was significantly different in groups (Group A = 7.20 ± 1.13 , Group B = 8.30 ± 1.113 , P-value < 0.05). The post-operative wound complications were manageable so the hospital stay of these patients reduces. The limitation of current study is the small sample size and study design. As we have only 10 patients in endoscopic harvesting group. We also have inadequate experience for grafting because this is a new technique for us. It requires trained and experienced surgeons. We also lack the long term follow up of patients regarding graft patency for each group.

Conclusions:

Endoscopic radial artery harvest is best suited technique for CABG surgery as it significantly decreases the harvest time as well as hospital stay. It is also proven that it is safer, less painful and better wound appearance technique with exceptional outcomes based on positive surgical experience.

References:

1. Parolari A, Rubini P, Alamanni F et al (2000) The radial artery: which place in coronary operation? *Ann. Thorac. Surg.* **69**:1288–1294.
2. Fukui T (2019). Bilateral Internal Thoracic Artery Graft in Coronary Artery Bypass Grafting. *Journal of Coronary Artery Disease.* **25**(2):21–6.
3. Melly L, Torregrossa G, Lee T, Jansens JL, Puskas JD (2018). Fifty years of coronary artery bypass grafting. *Journal of Thoracic Disease.* **10**(3):1960.
4. Acar C, Jebara VA, Portoghese M, Beyssen B, Pagny JY, Grare P et al (1992) Revival of the radial artery for coronary artery bypass grafting. *Ann. Thorac. Surg.*, **54**:652–660
5. Calafiore AM, Di Giammarco G, Luciani N, Maddestra N, Di Nardo E, Angelini R (1994) Composite arterial conduits for a wider arterial myocardial revascularization. *Ann. Thorac. Surg.* **58**:185–190
6. Navia JL, Brozzi N, Chiu J et al (2012) Endoscopic versus open radial artery harvesting for coronary artery bypass grafting. *J. Cardiovasc. Surg. (Torino)*, **53**: 257–263
7. Allen KB, Cheng B, Cohn W, Connolly MW, Edgerton J, Falk V, Martin J, Ohtsuka T, Vitali RM (2005): Endoscopic vascular harvest in coronary artery bypass grafting surgery: a consensus statement of the International Society of Minimally Invasive Cardiothoracic Surgery (ISMICS). *Innovations.* 51–60.
8. Acar C, Buxton B, Norsworthy C, Eizenberg N, Taggart D et al (1999) Radial artery. In: Buxton B, Frazier OH, Westaby S (eds) *Ischemic heart disease surgical management.* Mosby, London, 151–157.
9. Collins P, Webb CM, Chong CF, Moat NE (2008) Radial artery versus saphenous vein patency randomized trial. Five-year angiographic follow-up. *Circulation*, **117**:2859–2864.
10. Cable DG, Caccitolo JA, Pearson PJ et al (1998). New approaches to prevention and treatment of radial artery graft vasospasm. *Circulation* 98: 1115–1121 discussion 1121–2.
11. Rodriguez E, Ormont ML, Lambert EH et al (2001). The role of preoperative radial artery ultrasound and digital plethysmography prior to coronary artery bypass grafting. *Eur. J. Cardiothorac. Surg.*, **19**:135–139.
12. Allen RH, Szabo RM, Chen JL (2004). Outcome assessment of hand function after radial artery harvesting for coronary artery bypass. *J. Hand. Surg. Am.*, **29**: 628–637.
13. Brodman RF, Hirsh LE, Frame R (2002). Effect of radial artery harvest on collateral forearm blood flow and digital perfusion. *J. Thorac. Cardiovasc. Surg.* **123**:512–516.

14. Patel AN, Henry AC, Hunnicutt C, Cockerham CA, Willey B et al (2004). Endoscopic radial artery harvesting is better than the open technique. *Ann. Thorac. Surg.*, **78**:149-153.
15. Connolly MW, Torrillo LD, Stauder MJ, Patel NU, McCabe JC et al (2002). Endoscopic radial artery harvesting: result of first 300 patients. *Ann. Thorac. Surg.* **74**:502-506
16. Kiaii BB, Swinamer SA, Fox SA, Stitt L, Quantz MA, Novick RJ (2017). A prospective randomized study of endoscopic versus conventional harvesting of the radial artery. *Innovations*, **12**(4):231-8.
17. Kim G, Jeong Y, Cho Y, Lee J, Cho J (2007). Endoscopic radial artery harvesting may be the procedure of choice for coronary artery bypass grafting. *Circ. J.* **71**:1511-1515.
18. Leonard JR, Abouarab AA, Tam DY, Girardi LN, Gaudino MF, Femes SE (2018). The radial artery: Results and technical considerations. *Journal of Cardiac Surgery*, **33**(5):213-8.19. Patel AN, Henry AC, Hunnicutt C, Cockerham CA, Willey B, Urschel HC Jr (2004). Endoscopic radial artery harvesting is better than the open technique. *Ann. Thorac. Surg.* **78**:149153.
19. Gaudino MF, Lorusso R, Ohmes LB, Narula N, McIntire P, Gargiulo A, Bucci MR, Leonard J, Rahouma M, Di Franco A, He GW (2019). Open radial artery harvesting better preserves endothelial function compared to the endoscopic approach. *Interactive Cardiovascular and Thoracic Surgery.* **29**(4):561-7.