

**Case Report****Traumatic Anterolisthesis with Pre-Existing Idiopathic Scoliosis: An Unusual Case Report**Atif Raza¹, Binash Afzal¹, Baseerat Iqbal¹ and Zeeshan Amjad¹¹Riphah College of Rehabilitation and Allied Health Sciences, Riphah International University, Lahore, Pakistan**ARTICLE INFO****Key Words:**

anterolisthesis, low back pain, cryotherapy

How to Cite:

Raza, A., Afzal, B., Iqbal, B., & Amjad, Z. (2022). Traumatic Anterolisthesis with pre-existing idiopathic scoliosis: An unusual case report : Traumatic Anterolisthesis with Pre-Existing Idiopathic Scoliosis. *Pakistan BioMedical Journal*, 5(7). <https://doi.org/10.54393/pbmj.v5i7.602>

***Corresponding Author:**

Atif Raza
Riphah College of Rehabilitation and Allied Health Sciences, Riphah International University, Lahore, Pakistan
atifraza18@yahoo.com

Received Date: 5th July, 2022

Acceptance Date: 17th July, 2022

Published Date: 31st July, 2022

ABSTRACT

Low back pain may have different causes and one of the cause is anterolisthesis. Anterolisthesis is the anteriorly slippage of a vertebrae onto its caudal one. Its Grading is done using mayerding classification system on a plain radiograph in oblique view. Grade I is identified less than the 25% of slippage, in grade II its 25 to 50%, grade III of 51 to 75%, and grade IV having 76 to 100% of slippage. Sometimes it may be symptomatic as well as asymptomatic; pattern of pain is usually localized and/or referred to the dermatome of slipped vertebrae. Non-operative management is preferred as long as failure of non-operative management and neurological deficit. Case Summary: we presented the case of traumatic anterolisthesis of grade I with the preexisting idiopathic scoliosis. Cases with other conditions have been reported before like spondylolysis but not with scoliosis. Case was diagnosed with plain radiography as well as physical examination. The condition was managed with physical therapy. Conclusion: Grade I anterolisthesis can be manageable with non-operative methods such as physical therapy. Cryotherapy is found to provide maximum relive of inflammation based pain than thermotherapy. Early diagnosis and treatment is beneficial to rescue patient from state of kinesophobia.

INTRODUCTION

Degenerative spondylolisthesis is defined the degeneration or wear and tear of the spinal components including intervertebral discs, spinal ligaments and weakening of para spinal muscles, was divided into two categories according to the direction of slippage: retrolisthesis (posteriorly slipped vertebrae on its caudal one) and anterolisthesis (anteriorly slipped vertebrae on the other one)[1]. Whereas Traumatic spondylolisthesis is an uncommon entity reported in the literature [2]. prevalence of spondylolisthesis among the patients of low back pain was recorded at 7.4% [3]. On the other hand, Scoliosis is multi-dimensional abnormality of the spine identified by a lateral deviation of at least 10 degrees with rotation in the spine, usually accompanied by a decrease in the normal kyphosis of the spine known as hypokyphosis. It

is justified in three types as neuromuscular, congenital or idiopathic [4]. At the best of our knowledge, we present a rare case of L4 traumatic anterolisthesis with the pre-existing idiopathic scoliosis which has not been presented in the literature yet and to discuss its management with the non-operative methods.

CASE

A 55 years old house wife came up with two days' history of severe pain in the lower back, medial buttock and lateral thigh. The pain started after she lifted a weight from the ground in flexed spine. Physical examination presented very less mobility in extension of spine and radicular symptoms on provoking. Intensity of pain was gradually increasing after walking a few steps and as well as prolonged sitting. Severe tenderness was felt at L4-L5

region of low back. Radiographs showed Grade-I anterolisthesis at L4 vertebra according to mayerding classification system as well as pre-existing idiopathic scoliosis is determined. Natural tone of para spinal muscles was preserved. Inter vertebral spaces were very narrow than normal.[Figure 2]

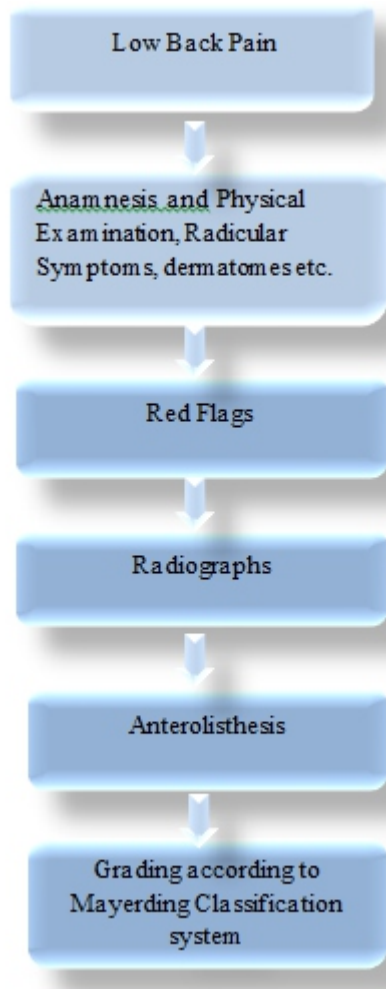


Figure 1: Flow chart Of Assesment

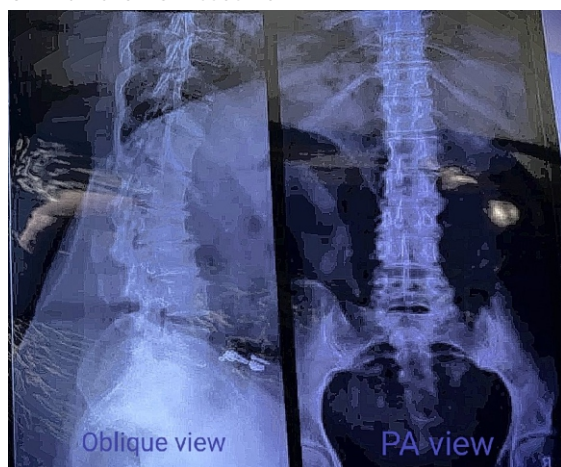

Figure 2: Showing anterolisthesis in oblique view and scoliosis in

PAview

Since, there were no neurological deficits such as impingement of spinal nerve. So, it was finalized not to operate and remaining options were analgesics and physical therapy. Patient have done with stomach flushing due to GERD(gastroesophageal reflux disease) just before 2 days of the onset of this conditions and analgesics like NSAIDS cannot be used in GERD. The only course of action was to manage through physical therapy. Patient was advised to abstain from daily activities and wear lumbo-sacral orthosis at sitting and walking. Cryotherapy was used for the localized pain at L4-L5 level. Spinal Flexion based exercises were more emphasized as they relieve symptoms in anterolisthesis, Active contraction of the abdominal muscles e.g. knee to chest and isometrics of the lower back muscles. Cat and Camel exercise was also the part of regime. After 12 days of sessions patient reported she can perform pain free movements. After It Co-contraction exercises for core stability and proprioceptive stimulations were used to enhance the ability to perform ADLs hazard-free. Daily sessions were conducted for 15 days and day after day sessions were conducted for another 15 days.

DISCUSSION

At the best of our knowledge, we present a rare case of L4 traumatic anterolisthesis with the pre-existing idiopathic scoliosis which has not been revealed in the literature yet and discuss its management with the non-operative methods. In literature occurrence of anterolisthesis with other conditions such as pedicle fracture have been reported [5] Assessment of a patient with symptomatic anterolisthesis which is the type of spondylolisthesis includes the history, radiographic imaging(X-Rays) as well as physical examination, which also helps in identifying the yellow and red flags as highlighted by the Finucane LM et al [6]. Location of pain itself does not help to differentiate the symptomatic lumbar spondylolisthesis from unparticular LBP. Indeed, pain may be present at both lumbar region and/or referred to the legs. Keeping in mind that pain of lower back comes from many causes, other symptoms must be analyzed to develop a differential diagnosis among conditions having similarity with non-specified LBP (in which occurrence of spondylolisthesis is not relating to the symptoms), and other situations in which the LBP is rationally linked to SPL, when the instability is present at lumbar and its effects are the important feature of assessment [7]. Clinical testing for the symptomatic lumbar SPL may be categorized into different kinds dependent on the purpose. The purpose of these tests is to detect anatomical defects, assess vertebral mobility, provoking/relieving of pain and other marks such as paresthesia, assessing lumbar muscles endurance [8].

Static X-rays have been proven gold standard till date for the determination of SPL when a glide > 3mm in the oblique view is observed as concluded by the Simmonds et al. in his systematic review [9], In this case we used plain radiographs(x-rays) in oblique view stood up to determine the anterolisthesis as reported by the Kuhns BD et al. that Standing Oblique X-rays have a more sensitivity to rule out SPL as compared to supine MRI [10]. In this case It is discovered that anterolisthesis is of Grade I. Grading of the anterolisthesis is very important in aspect of prognosis and clinical decisions like surgery. Mayerding classification system is the commonest used as it's easy to employ. Grade I is identified less than the 25% of slippage, in grade II its 25 to 50%, grade III of 51 to 75% and grade IV having 76 to 100% of slippage [11]. In this case Treatment segment was consist of non-operative management. As endorsed by the Van der Heijden et. al in his case report that indications for surgery include failure of non-operative management and occurrence of neurological deficit [5]. During assessment, patient education should be the important element as it facilitates the changes in behavior. Bearing in mind that the weaker association between the LBP and SPL, the SPL diagnosis should not cause panic for the patient [12]. In this case our first step in course of action was to manage pain. Highly perceiving pain decreases self-awareness in pain and increases the kinesiophobia as highlighted by La Touche et al [13]. In this case localized pain was manage with the help of cryotherapy. In a clinical trial of Morteza Dehghan, he verified that cryotherapy is a significant good approach to relive inflammation and pain than thermotherapy [14]. In this case flexion based exercises of spine were more emphasized as well as cat and camel exercise. Underlying mechanism was employing of tension in the spinal ligaments to realign the slipped vertebrae. Where as in retrolisthesis, extension based exercises are found to efficient facilitated by the latest study of Contreras et. Al [15].

CONCLUSION

Proper Assessment and differential diagnosis is the key to the right direction of treatment. Grade I anterolisthesis can be manageable with non-operative methods such as physical therapy. Cryotherapy is found to provide maximum relive of inflammation based pain than thermotherapy. Early diagnosis and treatment is beneficial to rescue patient from state of kinesiophobia and patient education have a key role in developing synergy with patient and activation of good cellular brain mechanisms which may help in fast healing.

REFERENCES

[1] Zhu F, Bao H, Liu Z, Zhu Z, He S, Qiu Y. Lumbar retrolisthesis in aging spine. *Clinical Spine Surgery*.

2017; 30(6):E677-E82.

- [2] Deniz FE, Zileli M, Çağlı S, Kanyılmaz H. Traumatic L4-L5 spondylolisthesis: case report. *European Spine Journal*. 2008 Sep; 17 Suppl 2(Suppl 2):S232-5. doi: 10.1007/s00586-007-0496-6.
- [3] Aoki Y, Takahashi H, Nakajima A, Kubota G, Watanabe A, Nakajima T, et al. Prevalence of lumbar spondylolysis and spondylolisthesis in patients with degenerative spinal disease. *Scientific Reports*. 2020 Apr; 10(1):6739. doi: 10.1038/s41598-020-63784-0.
- [4] Choudhry MN, Ahmad Z, Verma R. Adolescent idiopathic scoliosis. *The open orthopaedics journal*. 2016 May; 10:143-54. doi: 10.2174/18743250 016100 10143.
- [5] Van der Heijden C, Claerbout M, Peers K, Lauweryns P. Traumatic lumbar pedicle fracture associated with pre-existing bilateral spondylolysis and anterolisthesis in a professional soccer player. *Journal of Back and Musculoskeletal Rehabilitation*. 2007 Jan; 20(2-3):131-4.
- [6] Finucane LM, Downie A, Mercer C, Greenhalgh SM, Boissonnault WG, Pool-Goudzwaard AL, et al. International framework for red flags for potential serious spinal pathologies. *Journal of orthopaedic & sports physical therapy*. 2020 Jul; 50(7):350-372. doi: 10.2519/jospt.2020.9971.
- [7] Petersen T, Laslett M, Juhl C. Clinical classification in low back pain: best-evidence diagnostic rules based on systematic reviews. *BMC musculoskeletal disorders*. 2017 May; 18(1):188. doi: 10.1186/s12891-017-1549-6.
- [8] Ahn K, Jhun H-J. New physical examination tests for lumbar spondylolisthesis and instability: low midline sill sign and interspinous gap change during lumbar flexion-extension motion. *BMC musculoskeletal disorders*. 2015 Apr; 16:97. doi: 10.1186/s12891-015-0551-0.
- [9] Simmonds AM, Rampersaud YR, Dvorak MF, Dea N, Melnyk AD, Fisher CG. Defining the inherent stability of degenerative spondylolisthesis: a systematic review. *Journal of Neurosurgery: Spine*. 2015 Aug; 23(2):178-89.
- [10] Kuhns BD, Kouk S, Buchanan C, Lubelski D, Alvin MD, Benzel EC, et al. Sensitivity of magnetic resonance imaging in the diagnosis of mobile and nonmobile L4-L5 degenerative spondylolisthesis. *The Spine Journal*. 2015 Sep; 15(9):1956-62. doi: 10.1016/j.spinee.2014.08.006.
- [11] Koslosky E, Gendelberg D. Classification in brief: the Meyerding classification system of spondylolisthesis. *Clinical orthopaedics and related*

- research. 2020 May; 478(5):1125-1130. doi: 10.1097/CORR.0000000000001153.
- [12] Andrade NS, Ashton CM, Wray NP, Brown C, Bartanusz V. Systematic review of observational studies reveals no association between low back pain and lumbar spondylolysis with or without isthmic spondylolisthesis. *European Spine Journal*. 2015 Jun; 24(6):1289-95. doi: 10.1007/s00586-015-3910-5
- [13] La Touche R, Salud CS, La Salle EU. of Fisioterapia, CS, de Madrid A, La EU, de Madrid. How does self-efficacy influence pain perception, postural stability and range of motion in individuals with chronic low back pain. *Pain Physician*. 2019; 22:E1-3.
- [14] Dehghan M, Farahbod F. The efficacy of thermotherapy and cryotherapy on pain relief in patients with acute low back pain, a clinical trial study. *Journal of clinical and diagnostic research: JCDR*. 2014 Sep; 8(9):LC01.
- [15] Contreras B, Schoenfeld B. To crunch or not to crunch: An evidence-based examination of spinal flexion exercises, their potential risks, and their applicability to program design. *Strength & Conditioning Journal*. 2011 Aug; 33(4):8-18.