

**Case Study****A Case of Lung Abscesses Secondary to Mucormycosis in a Diabetic Female Patient**

Rabia Seher Alvi¹, Kamran Khan Sumalani¹, Nausheen Saifullah¹, Sadhna Priya¹, Saifullah¹ and Rabia Javed¹

¹Jinnah Postgraduate Medical Center (JPMC), Karachi, Pakistan

ARTICLE INFO**Key Words:**

Fungal Infections, Tuberculosis, Bronchoscopy

How to Cite:

Alvi, R. S., Sumalani, K. K., Saifullah, N., Priya, S., Saifullah, & Rabia Javed. (2023). A Case of Lung Abscesses Secondary to Mucormycosis in a Diabetic Female Patient: Lung Abscesses Secondary to Mucormycosis. *Pakistan BioMedical Journal*, 6(07). <https://doi.org/10.54393/pbmj.v6i07.904>

***Corresponding Author:**

Rabia Seher Alvi
Jinnah Postgraduate Medical Center (JPMC),
Karachi, Pakistan
rabiaseheralvi@yahoo.com

Received Date: 14th May, 2023

Acceptance Date: 18th July, 2023

Published Date: 31st July, 2023

ABSTRACT

Mucormycosis is a rapidly advancing and hazardous form of opportunistic infection usually starts in nose and/or paranasal sinuses after inhaling fungal spores. This infection is caused by Mucorales fungi which belong to the Zygomycetes class. The incidence of Mucormycosis is approximately 1.7 cases in 1 million. They more frequently exist in rhinomaxillary area and is a rare pulmonary disease of an opportunistic fungi, which is difficult to diagnose with an unpredictable response to treatment. They usually appear in individuals with immunocompromised states such as diabetes, long term use of corticosteroids, immunosuppressive therapy for solid organ and hematopoietic cell transplantation, and disorders like neutropenia are notably common risk factors. As a potential for relatively life-threatening condition, the disorders warrant an anticipatory approach. We report here a case of pulmonary mucormycosis in uncontrolled diabetes presented with bilateral cavitary lesions in lungs that was first misdiagnosed as case of Pulmonary TB, later diagnosis was made on the basis of results of bronchoscopic biopsy, and was started on amphotericin and followed up with improvement of her symptoms.

INTRODUCTION

Mucormycosis is an uncommon invasive fungal infection of Mucorales class fungus, which is an order of filamentous fungi of family Mucoraceae. It is much more non frequent compared to other opportunistic infections like candida and aspergillus. There are six most common reported presentations of an infection of Mucormycosis including rhino cerebral infection, pulmonary, cutaneous or gastrointestinal infection as well as disseminated disease and some rather rare presentations [1]. Individuals who are living with Type 2 Diabetes, neutropenia, systemic administration of corticosteroids, chemotherapy, hematological malignancies (i.e. leukemia and lymphoma) are the frequent immunocompromised states in our setup [2]. Pulmonary invasion of mucormycosis mainly results

from inhalation of sporangiospores of the fungi or in some cases through hematogenous and/or lymphatic spread of the microscopic organism. Presenting complains tend to be nonspecific like cough, chest pain, dyspnea, fever and hemoptysis [3]. It is somewhat difficult to make diagnosis when the lungs are involved particularly when no reliable serological test, PCR or skin tests exists for Mucormycosis. Culture specimen of some other organism also does not rule out the concurrent mucormycosis infection. When in doubt, the clinician has to rely on histopathological specimen from affected soft tissue to make the definite diagnosis [4].

CASE REPORT

A 60-year-old female, came to outpatient clinic with the

chief complaints of productive cough and hemoptysis, significant weight loss for 4 months, generalized body weakness and lethargy for 1 month. Her previous medical history includes treated case of pulmonary tuberculosis on clinical grounds and uncontrolled diabetes for five years, her average fasting sugar levels were 342mg/dl and 3-month sugars control report are 13.9% HBA1C and drug history include noncompliance to oral hypoglycemic drugs and insulin. Patient was vitally stable, admitted to pulmonology ward for further proceedings. On General Physical Examination she was pale and skinny, on Chest examination there were crepitations in the right 4th to 6th ICS and left 3rd and 4th ICS. Her CBC was requested which revealed her hemoglobin to be 9.6gm/dl, platelets in range of 590/L and total WBC count of 8700 cells/dl. Biochemical investigations showed a BUN of 14.1mg/dl and creatinine 0.7mg/dl. Chest radiograph and CT chest contrast demonstrated bilateral cavitory lesions with air fluid levels in left upper lobe and right middle lobe suggestive of lung abscesses (Figure 1 and Figure 2). Sputum workup was done for microscopy and culture that came out to be negative.

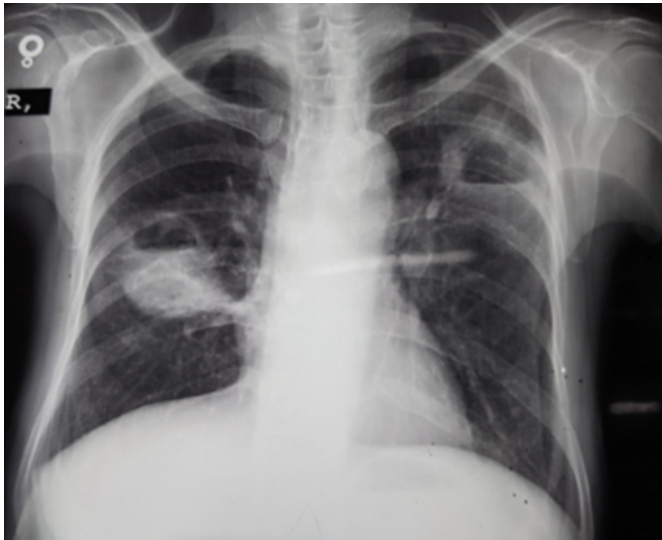

Figure 1: Shows bilateral lung abscesses

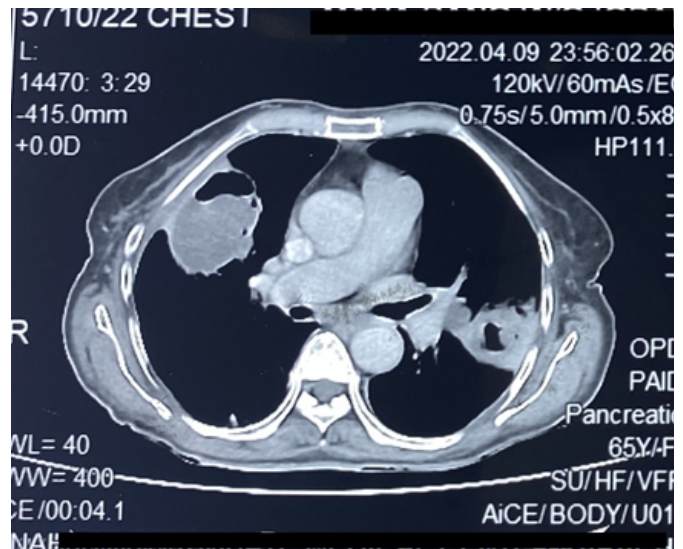


Figure 2: Demonstration of bilateral lung abscesses in the mediastinal window of CT chest

Bronchoscopy was performed that showed granulation tissue and grey white mucoid material seen in lateral segment of the right middle lobe blocking the airway lumen, left bronchial tree appeared to be normal with no sign of any endobronchial lesion or mucosal abnormalities, (Figure 3).

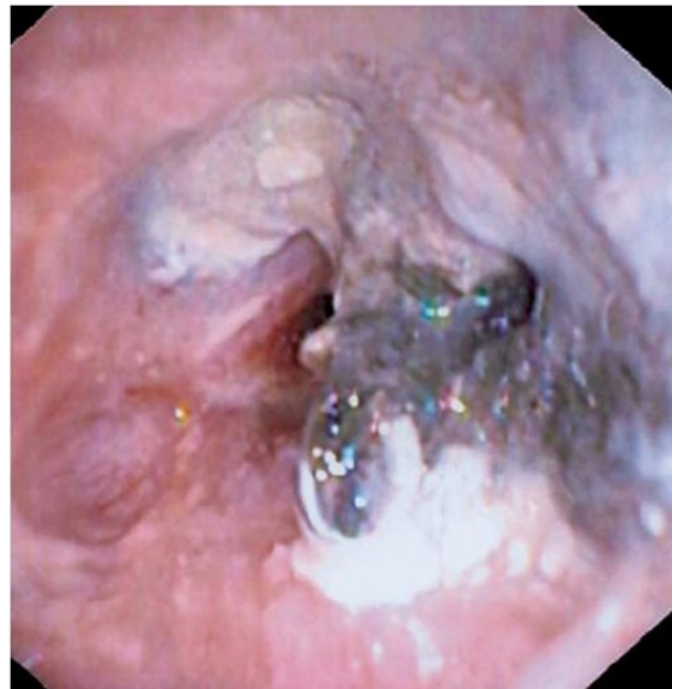

Figure 3: Granulation tissue with grey white mucoid material seen in lateral segment of right lower lobe

Bronchoalveolar lavage analysis showed inflammatory cells and degeneration of lining though cytology came out to be negative for any evidence of malignancy. Culture was also performed on cells from lavage with negative growth

after 5 days. Examination of AFB smear under light microscope, gene Xpert, AFB culture; all came out to be negative. Tissue sample were taken from lateral segment of middle lobe and sent for the pathological examination. Microscopic description showed bronchial mucosa in abundant necrotic debris containing numerous broad aseptate ribbon like fungal hyphae suggestive of Mucormycosis. Tissue culture showed no growth. After confirmation Amphotericin B 5mg/kg IV q24hr started and followed up at 6 weeks with recovery of clinical symptoms and radiologic improvement. (Figure 4 and Figure 5).

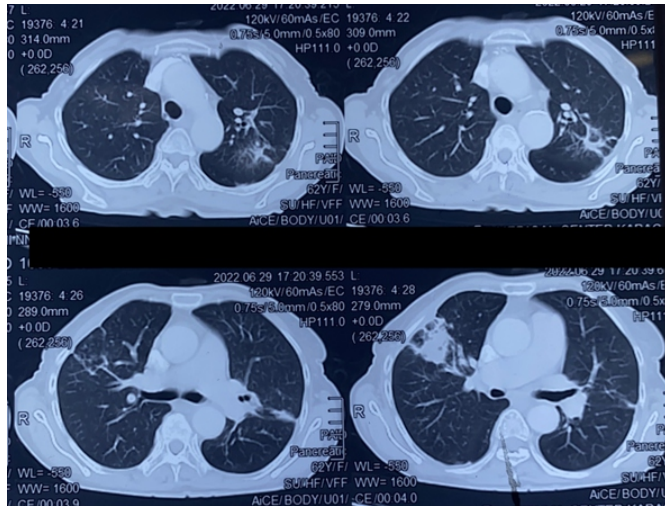


Figure 4: Radiologic improvement

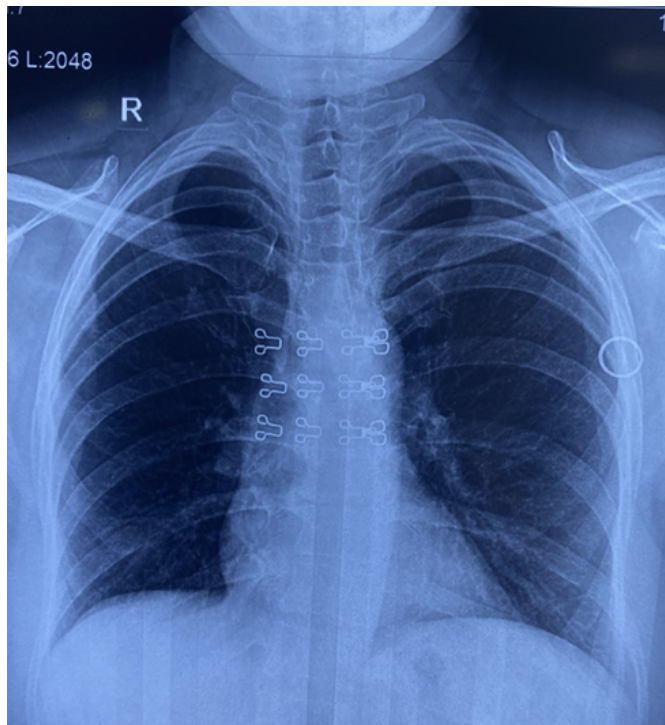


Figure 5: Follow-up chest X-ray shows dissolution of both abscesses

DISCUSSION

The present content reports the case of a middle aged diabetic female presented with chief respiratory complaints productive cough, dyspnea and weight loss with bilateral cavitory lesions on imaging and was misdiagnosed and treated as a case of pulmonary Tuberculosis but no response to the treatment although being compliant to it, admitted for bronchoscopic diagnostic workup ,that confirmed the growth of Mucorales thus was started on amphotericin and followed up with improvement of her symptoms and radiological improvements. Mucormycosis is the name given to group of infections caused by a fungus belonging to the order of Mucorales in taxonomic classification. It is highly invasive and is associated with high mortality, with the most common cause (65%) being Rhizopus [5]. Mucormycosis occurs almost exclusively in diabetic or immunocompromised patients through inhalation of spores [6]. There is no evidence of the transmission of this organism from person to person. Pulmonary symptoms are usually nonspecific including but not always limited to cough, chest pain, dyspnea and fever. Symptoms usually occur due to endobronchial lesions, and complications related to airway obstruction. Hemoptysis usually results from vascular involvement and can sometimes be fatal [3]. Radiographically, a range of findings may be present and are mostly nonspecific or with abnormal chest radiographs result are present in >80% of patients [7]. The findings may include nonspecific pulmonary infiltrates or nodules, and cavitated lesions which appear as 'halo' sign and Reversed halo sign [9]. Cavitory lesions with or without air-crescent signs are infrequent. The air-crescent sign which appear in almost 40% of the cases, generally portrays a poor prognosis if surgical intervention is delayed [8]. Also, cavitation may be more common in COVID-19 associated mucormycosis [9]. The definitive diagnosis of mucormycosis is dependent on histopathology and direct microscopy as well as culturing the organism through various clinical pathological and biopsy specimens. However cellular identification through sputum or Broncho-alveolar Lavage is unpredictable and cytology samples may come out to be negative most of the times [10, 11]. Thus, the most common method used for diagnosis of pulmonary mucormycosis is identification of characteristic fungal hyphae through microscopic examination of specimens obtained via flexible fiber-optic bronchoscopy [12]. The hyphae appear broad, non-septate filaments with branches at right angle on histopathological identification. The differentiation can be made from Aspergillus hyphae which shows regular, septate, and acute angle branching [13]. Treatment options for pulmonary mucormycosis involves a combination of

various surgical expurgations of the involved tissues in combination with antifungal therapy. However, in addition to those, removal of predisposing factors for infection are also necessary which may include strictly controlled blood sugar levels, correction of metabolic acidosis, administration of a chelating agent like deferoxamine, and correction of immunosuppressive state due to therapy or neutropenia etc. The antifungal agent; Amphotericin B in lipid formulation given intravenously is the drug of choice for initial therapy [14]. After the desired response is obtained the step-down therapy is initiated in the form of Posaconazole or Isavuconazole. In our case, we started the patient on amphotericin B (IV) with a dose of 5mg/kg daily alongside good control of sugars after which the scans were repeated that showed resolution of cavitory lesions with satisfactory control of symptoms.

CONCLUSIONS

Mucormycosis, though uncommon, is a serious infection affecting predominantly immunocompromised population. Non resolving Pneumonia and demonstration of cavities/abscesses on chest imaging could give a clue on further evaluation of such invasive fungal infections rather than predominant diseases like pulmonary tuberculosis in our system. To ensure better prognostic outcomes early diagnosis leading to prompt treatment that may include surgery as well as antifungal agents could result in better outcome and survival. Final diagnosis should be made on pathologic evidence of the organism's septate hyphae in damaged tissue after negative growth and culture of sputum and BAL samples. The physician should always have pulmonary Mucormycosis as his differentials in all the patients presenting with non-specific chronic pulmonary symptoms with negative cultures and carry out above mentioned promising diagnostic methods to ensure administration of correct treatment in the first presentation in order to promote better management for rare fungal infections in our setup.

Authors Contribution

Conceptualization: RSA, KKS

Methodology: NS, SPS

Formal analysis: NS, SP, S

Writing-review and editing: RSA, KKS, NS, SP, S, RJ

All authors have read and agreed to the published version of the manuscript.

Conflicts of Interest

The authors declare no conflict of interest.

Source of Funding

The author received no financial support for the research,

authorship and/or publication of this article.

REFERENCES

- [1] Pennell E, Pecson I, Nakamura C, Galvis AE. Pulmonary mucormycosis in an adolescent female with type 1 diabetes mellitus. *IDCases*. 2018 Jan; 14: e00474. doi: 10.1016/j.idcr.2018.e00474.
- [2] Serris A, Danion F, Lanternier F. Disease entities in mucormycosis. *Journal of Fungi*. 2019 Mar; 5(1): 23. doi:10.3390/jof5010023.
- [3] Spellberg B, Edwards Jr J, Ibrahim A. Novel perspectives on mucormycosis: pathophysiology, presentation, and management. *Clinical Microbiology Reviews*. 2005 Jul; 18(3): 556-69. doi: 10.1128/CMR.18.3.556-569.2005.
- [4] Mohammadi A, Mehdizadeh A, Ghasemi-Rad M, Habibpour H, Esmaeli A. Pulmonary mucormycosis in patients with diabetic ketoacidosis: a case report and review of literature. *Tuberk Toraks*. 2012 Jan; 60(1): 66-9. doi: 10.5578/tt.2464.
- [5] Roden MM, Zaoutis TE, Buchanan WL, Knudsen TA, Sarkisova TA, Schaufele RL, et al. Epidemiology and outcome of zygomycosis: a review of 929 reported cases. *Clinical Infectious Diseases*. 2005 Sep; 41(5): 634-53. doi: 10.1086/432579.
- [6] Kim Y, Lee KS, Jung KJ, Han J, Kim JS, Suh JS. Halo sign on high resolution CT: findings in spectrum of pulmonary diseases with pathologic correlation. *Journal of Computer Assisted Tomography*. 1999 Jul; 23(4): 622-6. doi: 10.1097/00004728-199907000-00025.
- [7] Donado-Uña JR, Díaz-Hellín V, López-Encuentra A, Echave-Sustaeta JM. Persistent cavitations in pulmonary mucormycosis after apparently successful amphotericin B. *European Journal of Cardio-Thoracic Surgery*. 2002 May; 21(5): 940-2. doi: 10.1016/S1010-7940(02)00081-7.
- [8] Wang XM, Guo LC, Xue SL, Chen YB. Pulmonary mucormycosis: a case report and review of the literature. *Oncology Letters*. 2016 May; 11(5): 3049-53. doi: 10.3892/ol.2016.4370.
- [9] Chung JH, Godwin JD, Chien JW, Pipavath SJ. Case 160: pulmonary mucormycosis. *Radiology*. 2010 Aug; 256(2): 667-70. doi: 10.1148/radiol.10081907.
- [10] Guarner J and Brandt ME. Histopathologic diagnosis of fungal infections in the 21st century. *Clinical Microbiology Reviews*. 2011 Apr; 24(2): 247-80. doi: 10.1128/CMR.00053-10.
- [11] Garg R, Marak RS, Verma SK, Singh J, Prasad R. Pulmonary mucormycosis mimicking as pulmonary tuberculosis: a case report. *Lung India: Official Organ of Indian Chest Society*. 2008 Jul; 25(3): 129. doi:

- 10.4103/0970-2113.59595.
- [12] Lee FY, Mossad SB, Adal KA. Pulmonary mucormycosis: the last 30 years. *Archives of Internal Medicine*. 1999 Jun; 159(12): 1301-9. doi: 10.1001/archinte.159.12.1301.
- [13] Song JG, Kang SH, Jung BW, Oh HS, Kim MJ, Lee SH. Invasive pulmonary aspergillosis histologically mimicking mucormycosis. *The Ewha Medical Journal*. 2016 Apr; 39(2): 65-8. doi: 10.12771/emj.2016.39.2.65.
- [14] Cornely OA, Alastruey-Izquierdo A, Arenz D, Chen SC, Dannaoui E, Hochhegger B, et al. Global guideline for the diagnosis and management of mucormycosis: an initiative of the European Confederation of Medical Mycology in cooperation with the Mycoses Study Group Education and Research Consortium. *The Lancet infectious diseases*. 2019 Dec; 19(12): e405-21.