



## Original Article

## Varicocele Surgery: Three Years Experience

Suleyman Sagır<sup>1</sup> and Mustafa Azizoglu<sup>2</sup><sup>1</sup>Department of Urology, Mardin Artuklu University, Artuklu, Turkey<sup>2</sup>Department of Pediatric Surgery, Dicle University, Sur, Turkey

## ARTICLE INFO

## Key Words:

Varicocele, Fertility, Men

## How to Cite:

Sagır, S. . & Azizoglu, M. . (2023). Varicocele Surgery: Three Years Experience: Varicocele Surgery. Pakistan BioMedical Journal, 6(08).  
<https://doi.org/10.54393/pbmj.v6i08.908>

## \*Corresponding Author:

Suleyman Sagır  
 Department of Urology, Mardin Artuklu University,  
 Medical School, Turkey  
[dr.sagiroglu414@gmail.com](mailto:dr.sagiroglu414@gmail.com)

Received Date: 25<sup>th</sup> July, 2023Acceptance Date: 17<sup>th</sup> August, 2023Published Date: 31<sup>st</sup> August, 2023

## ABSTRACT

Despite available treatments like varicocelectomy, a standard therapy remains controversial. Varicocele repair has shown promise in improving sperm parameters, but further research is needed, especially in nonobstructive azoospermia cases. Techniques such as microscopic testicular sperm extraction and intracytoplasmic sperm injection have shown some success in achieving pregnancies. **Objective:** To articulate our hands-on experience and understanding pertaining to varicocele. **Methods:** This study included patients who presented to our clinic due to varicocele and underwent surgical procedures between November 2020 and January 2023. **Results:** This research involved 26 varicocele patients, primarily age range was 27.5 years old. The majority (85%) had varicocele on the left side, and 15% had bilateral varicocele. The mean vein diameter was 3.58mm and 2.6mm for the left side and bilateral cases respectively, with a general average of 3.45mm. Analysis of sperm count, motility, and morphology reflected an average of 32.6 million/ml, 23.2%, and 5.23%, respectively. An average of 4.45 veins was ligated during surgery, with a slight variance based on the side. One patient lost approximately 85% of the testicular blood supply due to a complication during surgery, leading to testicle hardening without atrophy. Two patients experienced recurrence (7.6% recurrence rate). Negative and positive correlations were found between the number of ligated veins and preoperative sperm count ( $p=0.043$ ,  $r=-0.408$ ), and vein diameter and preoperative sperm morphology ( $p=0.004$ ,  $r=0.544$ ), respectively. **Conclusions:** Despite the limitations, our study provides valuable insights into the relationship between varicocele severity and sperm parameters.

## INTRODUCTION

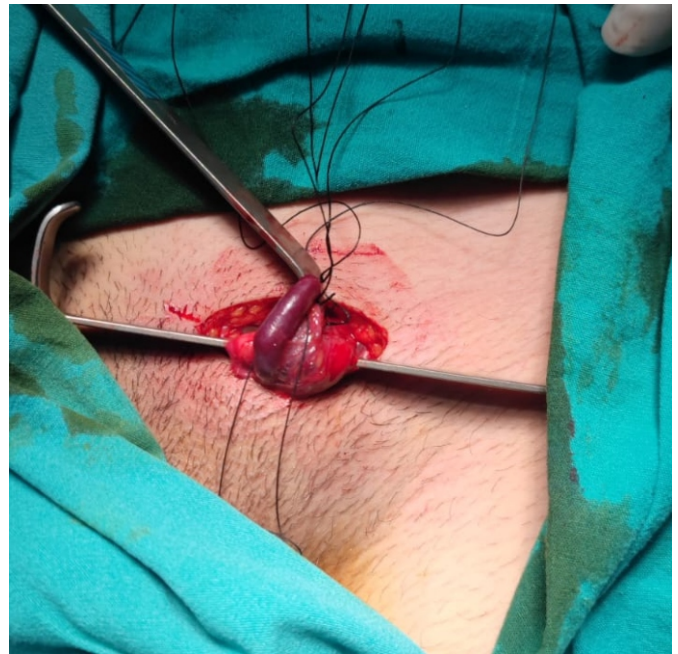Male fertility is affected by the frequent andrologic disorder known as idiopathic varicocele, particularly in hypofertile men. By lowering sperm quality and quantity, it affects reproductive potential. Sperm abnormalities including decreased motility, increased atypical forms, the presence of immature cells, and decreased sperm concentration are frequently seen in patients with varicoceles. Additionally, it has been noticed that 20% of people with varicoceles show abnormal spermatogenesis, while 14% of people with this disease who are hypofertile do not have any seminal abnormalities [1, 2]. Due to the lack of exact diagnostic techniques to determine fertility, the issue of treating varicoceles in childhood remains in controversial. Regardless of the severity of the varicocele, current

treatment decisions, such as varicocelectomy, are frequently based on detecting a smaller testicular volume on the affected side. Despite the wide range of available treatments, including open surgery, laparoscopy, retroperitoneoscopy, and percutaneous sclerosis, there is still no widely recognized gold standard therapy [1-3]. The preservation of the spermatic artery during the standard laparoscopic surgery of ligating spermatic arteries regularly presents medical professionals with challenges. The quality of spermiograms or the vascularization of the testicles, it is thought, may not be negatively impacted by internal inguinal ring ligation [3]. The most frequent reason for male infertility is varicocele, which is frequently reversible or improvable using a variety of surgical and

radiological procedures. Of male infertile with azoospermia, 5–10% have a clinical diagnosis. Varicocele repair (VR) has been shown to improve sperm concentration, motility, and morphology in oligozoospermic males, but further research is needed to determine how it affects testicular histological changes in nonobstructive azoospermia (NOA) cases. Being a father is strongly correlated with effective microscopic testicular sperm extraction (micro-TESE) and intracytoplasmic sperm injection (ICSI) in NOA-affected men [4]. However, ICSI only produces successful pregnancies in a small percentage of NOA instances. In 30–50% of couples where the male partner has NOA and spermatozoa have been detected on testicular biopsy, pregnancies and live births are accomplished. As a result, additional therapies are required to enhance sperm quality, sperm recovery chances, and testicular tissue repair [5]. Within the scope of this investigation, we sought to articulate our hands-on experience and understanding pertaining to varicocele.

## METHODS

This study included patients who presented to our clinic due to varicocele and underwent surgical procedures between November 2020 and January 2023. Patients with incomplete or inadequate data were excluded from the study. Data such as age, side, preoperative spermiogram parameters, preoperative ultrasound findings, and the number of veins ligated during surgery were recorded through the retrospective screening of patient files. Additionally, the recurrence rate was recorded and analyzed. All patients who presented to our clinic with symptoms of scrotal swelling and/or pain underwent a thorough history taking and physical examination. For all patients where there was a suspicion of varicocele based on the physical examination, a spermiogram, and an ultrasonography scan were requested. Surgical intervention was planned as necessary for relevant patients. A transverse skin incision measuring three centimeters is made over the external inguinal ring and continues until it reaches the Scarpa fascia. The index finger is then used to dissect the Scarpa fascia. Following the securing of the cord structures with an army-navy retractor, the Babcock clamp is used to grip the cord structures. Incisions are made in the external spermatic fascia with the assistance of a surgical microscope, and 4-0 ties are used to ligate all of the veins that are located within the spermatic cord as shown in the Figure 1 [6].



**Figure 1:** Intraoperative view

Approval from the local ethics committee at Siirt University was acquired with the number 4795 and date 11.05.2023. A variety of statistical techniques were used to examine the patient data, including the creation of descriptive statistics, frequency calculations, and evaluation of additional characteristics across all categories. Standard deviation and mean were used to express quantitative data. Pearson correlation test was used to test the correlation between items. IBM Corp., Armonk, New York, USA, provided SPSS Statistics for Windows, Version 24.0, for the processing of the data. Statistical significance was determined to be a two-tailed p-value of 0.05 or lower.

## RESULTS

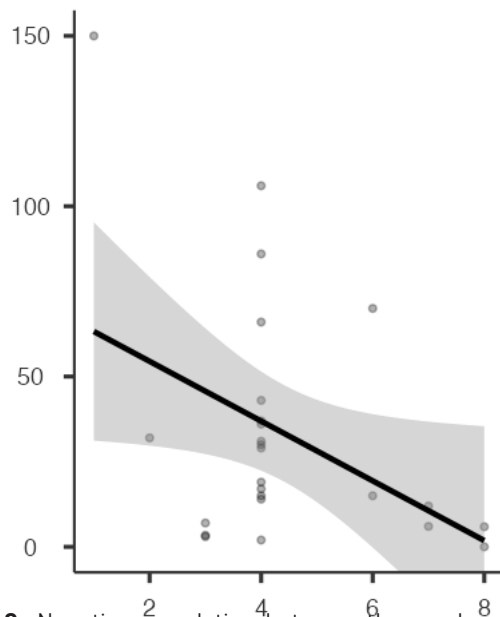
This study consisted 26 patients with varicocele. Table 1 indicates the average age of the patients was  $27.5 \pm 8.55$  years. Varicocele was found predominantly on the left side in 22 patients (85%), while it was bilateral in 4 patients (15%). The mean vein diameter on the left side was  $3.58 \pm 0.90$ mm. For the patients with bilateral varicocele, the average vein diameter was  $2.6 \pm 0.31$ mm. The average vein diameter for all cases was  $3.45 \pm 0.91$ mm. Analysis of the spermiograms showed an average sperm count of  $32.6 \pm 36.2$  million/ml, sperm motility was at an average of  $23.2 \pm 17.7\%$ , and the average normal sperm morphology was found to be  $5.23 \pm 11.6\%$ . The average number of veins ligated during surgery was  $4.40 \pm 1.71$  on the left side and  $4.75 \pm 1.26$  for bilateral cases. The average for all cases was  $4.45 \pm 1.64$ . A complication occurred in one patient during the procedure. In the patient who experienced the complication, about 85% of the testicular blood supply was lost. For this patient, no blood flow was detected in the postoperative ultrasound

scan, and it was observed that the testicle had hardened but no atrophy had occurred. The patient continues to attend routine check-ups. Out of the 26 patients, recurrence was observed in 2 patients, representing a recurrence rate of 7.6% (one of them from right and one from the left)

**Table 1:** Patients demographics

Variables	n(%) or Mean (SD)
Age	27.5±8.55
<b>Side</b>	
Left	22(85%)
Bilateral	4(15%)
<b>Vein diameter</b>	
Left	3.58±0.90
Bilateral	2.6±0.31
All cases	3.45±0.91
<b>Spermiogram</b>	
Count (M/mL)	32.6±36.2
Sperm motility (%)	23.2±17.7
Sperm morphology (%)	5.23±11.6
<b>Number of ligated veins</b>	
Left	4.40±1.71
Bilateral	4.75±1.26
All cases	4.45±1.64
Complication	1(3.8%)
Recurrence	2(7.6%)

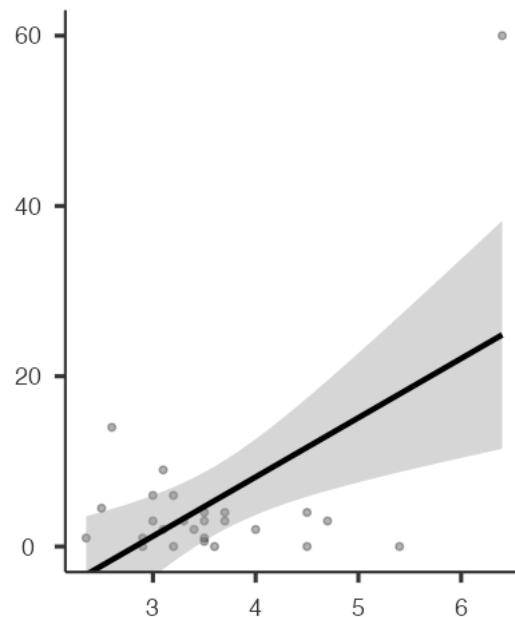
As shown in Figure 2, negative correlation was found between the number of veins ligated during surgery and the number of sperm detected during the spermiogram in the preoperative period ( $p=0.043$ ,  $r=-0.408$ ).



**Figure 2:** Negative correlation between the number of veins ligated during surgery(x)and the number of sperm(y)

In Figure 2, a positive correlation was found between the vein diameter and the sperm morphology detected during

the spermiogram in the preoperative period ( $p=0.004$ ,  $r=0.544$ ).



**Figure 3:** Positive correlation between the vein diameter (x) and the sperm morphology(y)

## DISCUSSION

Since the first varicocelectomy was demonstrated to improve semen parameters in 1952 [7], researchers have extensively tested this surgery. Numerous investigations, some of which were randomized clinical trials, revealed general improvements following surgery and offered strong support for the course of treatment. In one meta-analysis, total motility increased by 10.86% (95% CI, 7.07-14.65;  $p$  0.0001), progressive motility increased by 9.69% (95% CI, 4.86-14.52;  $p$  = 0.003), and sperm concentration increased by 12.32 million sperm per milliliter (95% CI, 9.45-15.19;  $p$  0.0001), respectively [8]. Our study involving 26 varicocele patients provides several insightful findings which can further contribute to the body of knowledge regarding varicocele management. Varicocele, often left-sided due to anatomical reasons, was observed predominantly on the left side in 85% of our study population, a finding consistent with previous literature [4, 8]. Additionally, 15% of our patients presented with bilateral varicocele, reiterating the importance of thorough examination in clinical practice to determine the extent and severity of the condition. The mean vein diameters we found, both in unilateral and bilateral cases, underline the considerable variation in the anatomy of varicoceles. This underscores the need for individualized approach to each case, as varicoceles are not uniform in presentation or severity. Regarding fertility parameters, the spermiogram analysis reflects a critical concern surrounding varicocele: its potential detrimental impact on sperm parameters [9].

The average sperm count, motility, and morphology in our study suggest a range of effects on spermatogenesis. However, the complexity of this relationship warrants further investigation, given the wide range of reported parameters. Our study identified a negative correlation between the number of ligated veins and preoperative sperm count. This suggests that the more extensive the varicocele (reflected by a larger number of ligated veins), the more likely it is to affect sperm production, potentially due to increased testicular temperature or venous pressure. However, the negative impact on sperm count could be mitigated with surgical intervention, emphasizing the role of timely and appropriate surgical management in preserving fertility. Interestingly, we observed a positive correlation between vein diameter and preoperative sperm morphology. This potentially indicates that larger veins, possibly indicative of more severe varicocele, could result in a higher incidence of abnormal sperm morphology. This again stresses the importance of early detection and intervention to prevent or minimize any detrimental effects on sperm quality. The testicular artery can be preserved (3.5-20%), and the laparoscopic method has the benefit of isolating internal spermatic veins close to the left renal vein. Air embolism, unintentional arterial division, genitofemoral nerve injury, hydrocele, intestinal injury, and peritonitis are the most significant side effects of laparoscopic varicocelectomy and occur in 8-12% of patients [10]. We encountered one severe complication during our study: a significant loss of testicular blood supply in a patient during surgery. This unfortunate incident emphasizes the need for meticulous surgical technique and careful perioperative management in order to prevent such complications. Fortunately, this patient did not develop testicular atrophy, demonstrating the remarkable resilience and regenerative potential of testicular tissue. According to some authors, gubernacular veins, which are present in 71-79% of cases and are thought to be the cause of postoperative relapses, should be surgically ligated during microsurgical varicocelectomy in order to prevent this problem [11, 12]. By comparing varicocelectomy with and without the delivery of testis, Ramasamy and Schlegel found no appreciable differences in the rate of recurrence following the ligation or non-ligation of gubernacular veins [12]. The recurrence rate in our study was relatively low (7.6%), suggesting that surgical treatment for varicocele in our clinical practice is generally successful. However, recurrence underlines the need for careful postoperative follow-up and possibly the exploration of adjunctive treatments to improve outcomes. The laparoscopic method provides better visibility of vessels and vas deferens with a low recurrence rate (approximately 3%, 1%-14%) [13-17]. However, it carries a risk of testicular atrophy

if vasectomy is performed later. Scrotal antegrade sclerotherapy (SAS), first described by Tauber and Johnsen in the 1990s, has a recurrence rate of 10%-15% but a low hydrocele rate [18, 19]. In the study of Chung *et al.*, [20] 113 patients underwent scrotal antegrade sclerotherapy (n=57) or laparoscopic Palomo surgery (n=56) for varicocele. Both groups had significantly smaller testes before surgery. At the 12-month follow-up, no significant differences in clinical recurrences were found between the two groups

## CONCLUSIONS

Despite the limitations, our study provides valuable insights into the relationship between varicocele severity and sperm parameters. Further research with larger sample sizes and a focus on various influencing factors is needed to enhance our understanding of varicocele management.

## Authors Contribution

Conceptualization: SS

Methodology: SS, MA

Formal Analysis: SS, MA

Writing-review and editing: SS, MA

All authors have read and agreed to the published version of the manuscript.

## Conflicts of Interest

The authors declare no conflict of interest.

## Source of Funding

The authors received no financial support for the research, authorship and/or publication of this article.

## REFERENCES

- [1] Jensen CF, Østergren P, Dupree JM, Ohl DA, Sønksen J, Fode M. Varicocele and male infertility. *Nature Reviews Urology*. 2017 Sep; 14(9): 523-33. doi: 10.1038/nrurol.2017.98.
- [2] Masson P and Brannigan RE. The varicocele. *Urologic Clinics*. 2014 Feb; 41(1): 129-44. doi: 10.1016/j.ucl.2013.08.001.
- [3] Cho CL, Esteves SC, Agarwal A. Indications and outcomes of varicocele repair. *Panminerva Medica*. 2019 Jun; 61(2): 152-63. doi: 10.23736/S0031-0808.18.03528-0.
- [4] Johnson D and Sandlow J. Treatment of varicoceles: techniques and outcomes. *Fertil Steril*. 2017 Sep; 108(3): 378-384. doi: 10.1016/j.fertnstert.2017.07.020.
- [5] Silay MS, Hoen L, Quadackaers J, Undre S, Bogaert G, Dogan HS, et al. Treatment of Varicocele in Children and Adolescents: A Systematic Review and Meta-analysis from the European Association of Urology/European Society for Paediatric Urology Guidelines Panel. *European Urology*. 2019 Mar; 75(3): 448-61. doi: 10.1016/j.eururo.2018.09.042.
- [6] Kramolowsky EV, Wood NL, Donovan JF, Sandlow JI.

- Randomized comparison of open versus laparoscopic varix ligation for the treatment of infertility. *Journal of Urology*. 1997; 157(4): 143.
- [7] Tulloch WS. A consideration of sterility factors in the light of subsequent pregnancies. II. Subfertility in the male. *Edinburgh Medical Journal*. 1952 Mar; 59(3): T29.
- [8] Baazeem A, Belzile E, Ciampi A, Dohle G, Jarvi K, Salonia A, et al. Varicocele and male factor infertility treatment: a new meta-analysis and review of the role of varicocele repair. *European Urology*. 2011 Oct; 60(4): 796-808. doi: 10.1016/j.eururo.2011.06.018.
- [9] Majzoub A, Elbardisi H, Arafa M, Agarwal A, AlSaid S, Al Rumaihi K. Does the number of veins ligated during varicocele surgery influence post-operative semen and hormone results?. *Andrology*. 2016 Sep; 4(5): 939-43. doi: 10.1111/andr.12226.
- [10] Chan P. Management options of varicoceles. *Indian journal of urology: IJU: Journal of the Urological Society of India*. 2011 Jan; 27(1): 65. doi: 10.4103/0970-1591.78431.
- [11] Mirilas P and Mentessidou A. Microsurgical subinguinal varicocelectomy in children, adolescents, and adults: surgical anatomy and anatomically justified technique. *Journal of Andrology*. 2012 May; 33(3): 338-49. doi: 10.2164/jandrol.111.013052.
- [12] Beck EM, Schlegel PN, Goldstein M. Intraoperative varicocele anatomy: a macroscopic and microscopic study. *The Journal of Urology*. 1992 Oct; 148(4): 1190-4. 10.1016/S0022-5347(17)36857-X.
- [13] Kupis Ł, Dobroński PA, Radziszewski P. Varicocele as a source of male infertility-current treatment techniques. *Central European Journal of Urology*. 2015; 68(3): 365. doi: 10.5173/cej.2015.642
- [14] Practice Committee of the American Society for Reproductive Medicine. Report on varicocele and infertility: a committee opinion. *Fertility and Sterility*. 2014 Dec; 102(6): 1556-60. doi: 10.1016/j.fertnstert.2014.10.007.
- [15] Palomo A. Radical cure of varicocele by a new technique: preliminary report. *The Journal of Urology*. 1949 Mar; 61(3): 604-7. doi: 10.1016/S0022-5347(17)69113-4.
- [16] Lai CZ, Chen SJ, Huang CP, Chen HY, Tsai MY, Liu PL, et al. Scrotal Pain after Varicocelectomy: A Narrative Review. *Biomedicines*. 2023 Apr; 11(4): 1070. doi: 10.3390/biomedicines11041070.
- [17] Collodel G, Ferretti F, Masini M, Gualtieri G, Moretti E. Influence of age on sperm characteristics evaluated by light and electron microscopies. *Scientific Reports*. 2021 Mar 2; 11(1):4989. doi: 10.1038/s41598-021-84051-w.
- [18] Tauber R and Johnsen N. Antegrade scrotal sclerotherapy for the treatment of varicocele: technique and late results. *The Journal of Urology*. 1994 Feb; 151(2): 386-90. doi: 10.1016/S0022-5347(17)34956-X.
- [19] Shebl SE, Ali S, El Gammal A. Intraoperative hydrodissection and Doppler ultrasound during magnified varicocelectomy: A comparative study. *Archivio Italiano di Urologia e Andrologia*. 2023 Feb; 95(1). doi: 10.4081/aiua.2023.11008.
- [20] Chung KL, Hung JW, Yam FS, Chao NS, Li DC, Leung MW. Prospective randomized controlled trial comparing laparoscopic Palomo surgery vs scrotal antegrade sclerotherapy in adolescent varicocele. *The Journal of Urology*. 2023 Mar; 209(3): 600-10. doi: 10.1097/JU.0000000000003087.